

Clinical reports

List of Indications Treated by Jett Plasma Medical

jett
medical



February 2017

Table of Contents

1.Scars	3
1.1 Dr. Mohammad Ghazzawi / Derma Right / Amman – Jordan.....	3
1.2. Veronika Flašárová MD., Dermi Clinic, Brno, Czech Republic	4
2. Smoothing of the eyes wrinkles (non-invasive blepharoplasty)	5
2.1 Irena Pluhar, Praxis für ästhetische Dermatologie, Sauerlach – Germany	5
2.2 Dr. Zeyad Alhamdany, Iraq.....	19
2.3 Helena Flášarová MD., Dermi Clinic, Brno, Czech Republic	24
2.4 BIA ??	36
2.5 Diana Petrova, Salon “Effect”, Sofia, Bulgaria.....	38
2.6 Dr. Doris Wallentin, Vienna	53
2.7 Dr. Schoppelrey	54
2.8 Dr Bhavini Lodaya,Mumbai	55
2.9 Yuva Cosmoderm,Dr Trimbake	56
2.10 Joshi Hospital,Dr Mutalik.....	56
3. Fibroma	58
3.1 Irena Pluhar, Praxis für Ästhetische Dermatologie, Sauerlach - Germany.....	58
3.2 Veronika Flašárová MD., Dermi Clinic, Brno, Czech Republic	59
4. Seborrheic Keratosis.....	61
4.1 Dr. Mohammad Ghazzawi / Derma Right / Amman – Jordan.....	61
5. Skin Tags	62
5.1 Dr. Mohammad Ghazzawi / Derma Right / Amman – Jordan.....	62
6. Hemangioma	63
6.1 Irena Pluhar, Praxis für Ästhetische Dermatologie, Sauerlach – Germany.....	63
7. Face Lipomas	64
7.1 Veronika Flašárová MD., Dermi Clinic, Brno, Czech Republic	64
8. Telangiectasia	66
8.1 Veronika Flašárová MD., Dermi Clinic, Brno, Czech Republic	66
9. Nasolabial wrinkles.....	67
9.1 Veronika Flašárová MD., Dermi Clinic, Brno, Czech Republic	67

1.Scars

1.1 Dr. Mohammad Ghazzawi / Derma Right / Amman – Jordan

Treated area: Forehead

Patient: Female, 44

Previous undergone aesthetic surgery: None

Anaesthesia: Infiltration with lidocaine 2%

The method: dot-by-dot and only scanning

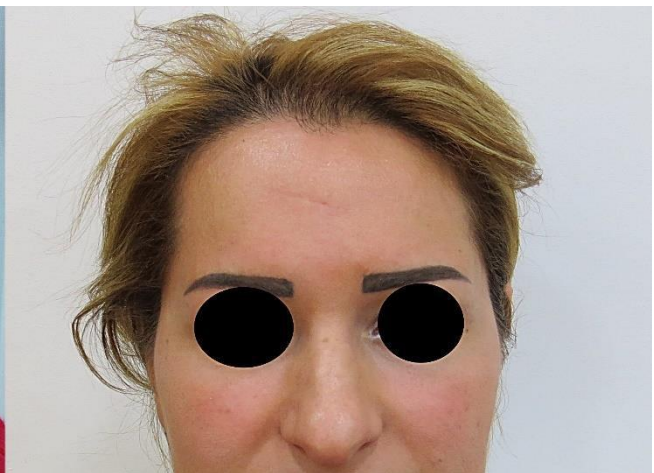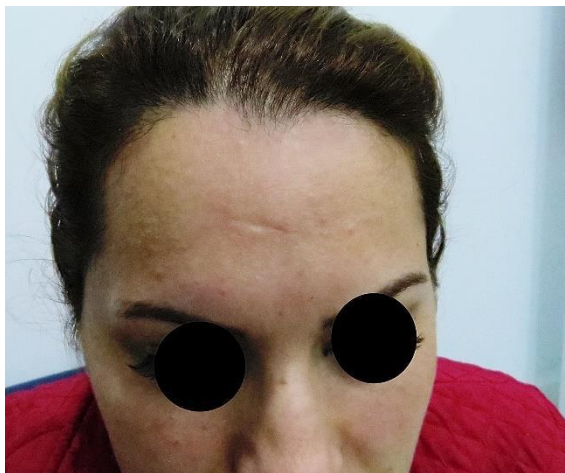Post treatment: MEBO

Time of healing: 5 Days

Side effects: None

18th February 2016

20th May 2016



1.2. Veronika Flašárová MD., Dermi Clinic, Brno, Czech Republic

Treated area: above the sternal notch

Patient: Female, 25

Previous undergone aesthetic surgery: None

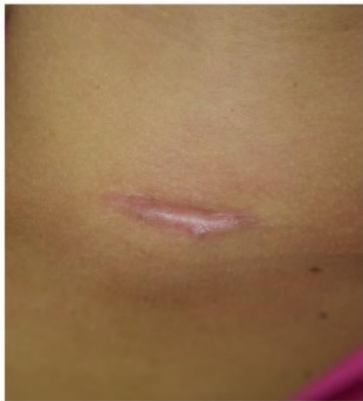Anaesthesia: local injection, lidocaine 5%

The method: scanning, until the raised portion is burnt

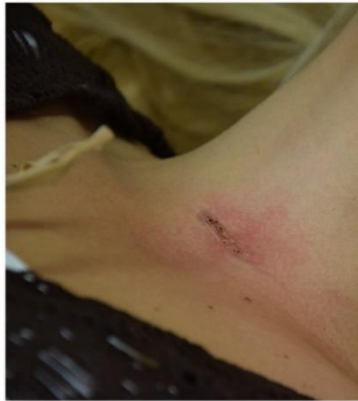Post treatment: sun protection one month (SPF 50+), regenerating cream

Time of healing: one week

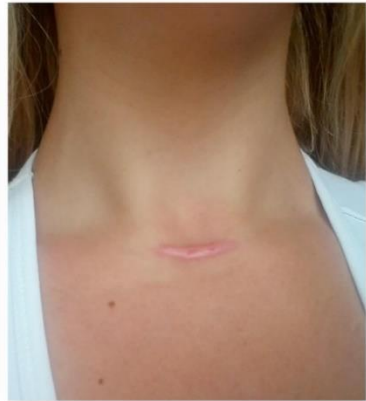Side effects: None



Before



Immediately
after



One week
after

2. Smoothing of the eyes wrinkles (non-invasive blepharoplasty)

2.1 Irena Pluhar, Praxis für ästhetische Dermatologie, Sauerlach – Germany

Treated area: Lower eyelids, lateral folds, both eyes

Patient: Female, 50

Previous undergone aesthetic surgery: None

Anaesthesia: Local Lidocain-Crème with 20% Lidocain, 5 % Tetracaine with occlusion

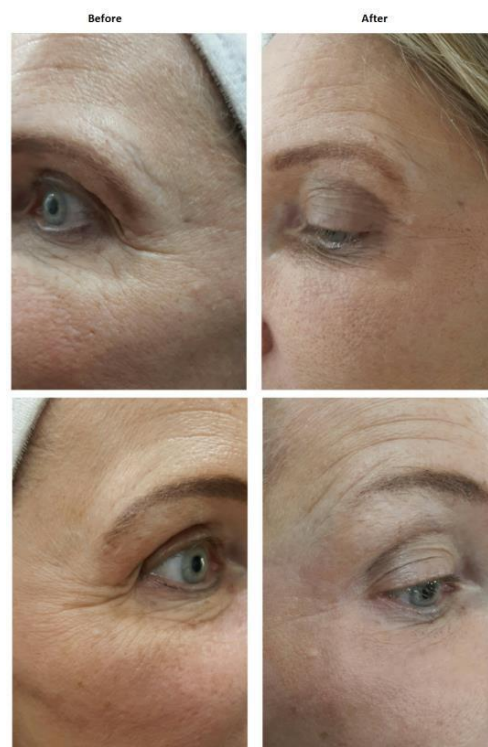The method: 5 minutes of scanning for one lower eyelid, dot-by-dot technique

Post treatment: Wash only with nuclear soap, as long as the crust exists. After washing, lightly dab with alcohol-free disinfectant. Daytime Oxygenetyx - special cream with UV protection and healing substances. For the night no care, dry cure. In case of strong sensitivity and redness, antiseptic gel. After heal the crust sun protection and hyaluronic gel

Time of healing: After 2 days crusts, after one week regenerated skin

Side effects: None

Date of photos: 15.9.2016, 29.9.2016



Treated area: Lower eyelids

Patient: Female, 52

Previous undergone aesthetic surgery: None

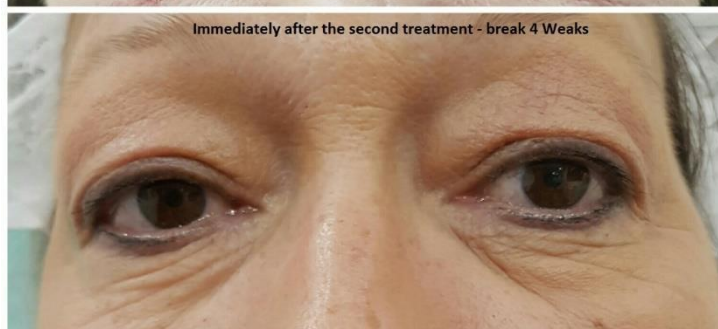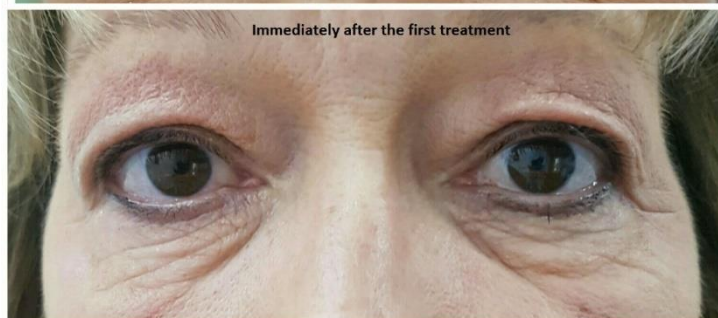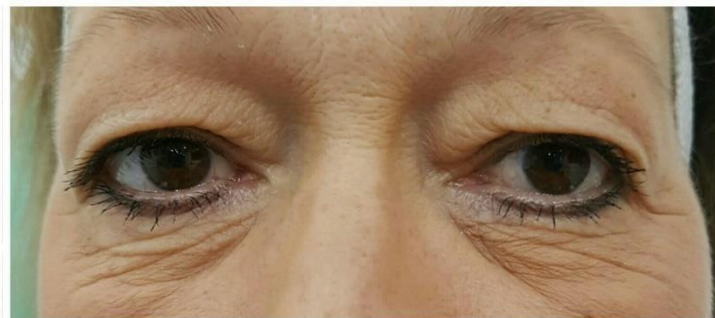Anaesthesia: Local Lidocain-Crème with 20% Lidocain and 5 % Tetracaine with occlusion

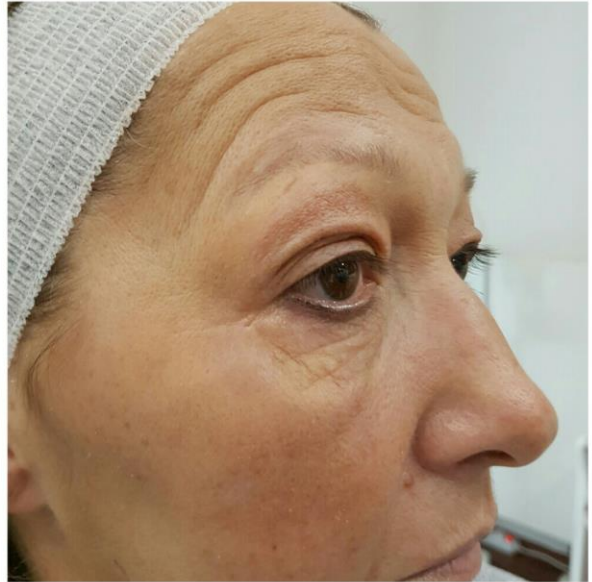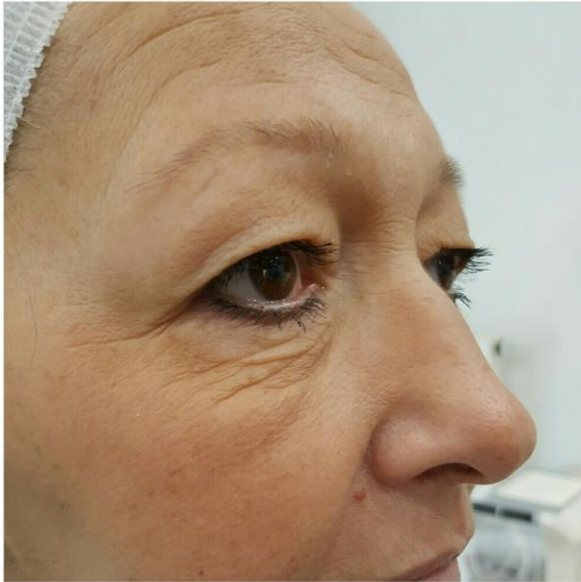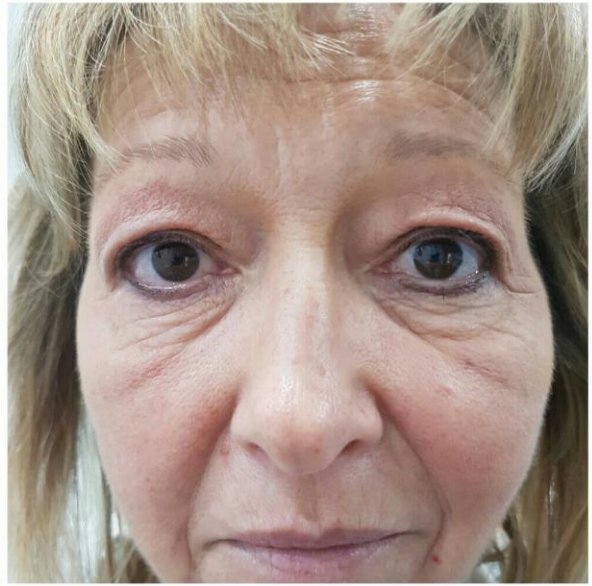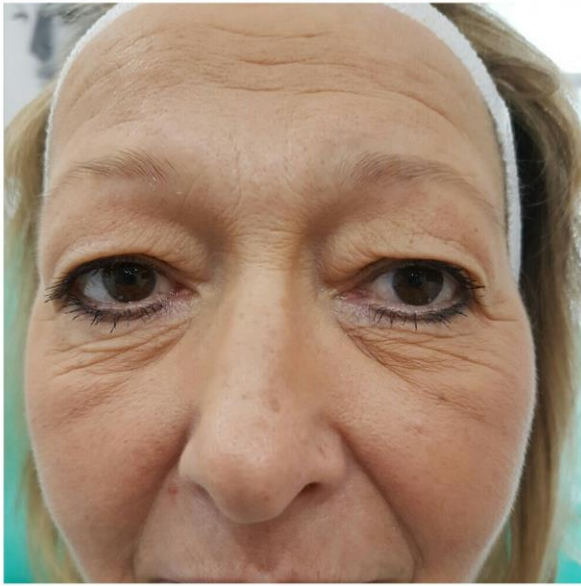The method: 5 minutes of scanning for one lower eyelid, dot-by-dot technique

Post treatment: Wash only with nuclear soap, as long as the crust exists. After washing, lightly dab with alcohol-free disinfectant. Daytime Oxygenetyx - special cream with UV protection and healing substances. For the night no care, dry cure. In case of strong sensitivity and redness, antiseptic gel. After heal the crust sun protection and hyaluronic gel

Time of healing: After 2 days crusts, after one week regenerated skin)

Side effects: None





Treated area: Upper eyelids, both eyes

Patient: Female, 35

Previous undergone aesthetic surgery: None

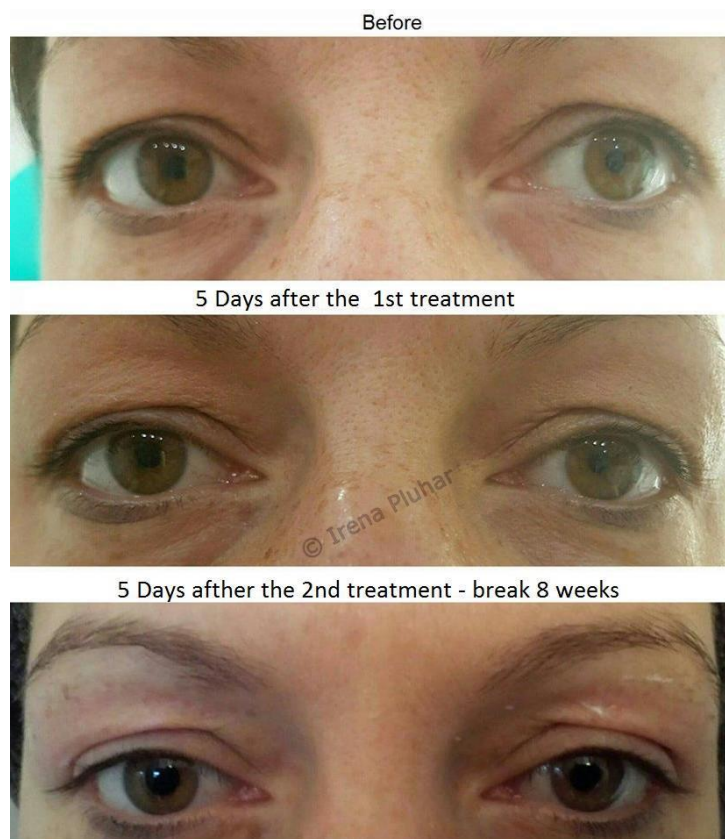Anaesthesia: Local Lidocain-Crème with 20% Lidocain and 5 % Tetracaine with occlusion

The method: 5 minutes of scanning and after dot-by-dot for one upper eyelid

Post treatment: Wash only with nuclear soap, as long as the crust exist. After washing, lightly dab with alcohol-free disinfectant. Daytime Oxygenetyx - special cream with UV protection and healing substances. For the night no care, dry cure. In case of strong sensitivity and redness, antiseptic gel. After heal the crust sun protection

Time of healing: After 2 days crusts, after one week regenerated skin

Side effects: None



Treated area: Upper eyelids, both eyes

Patient: Female, 34

Previous undergone aesthetic surgery: None

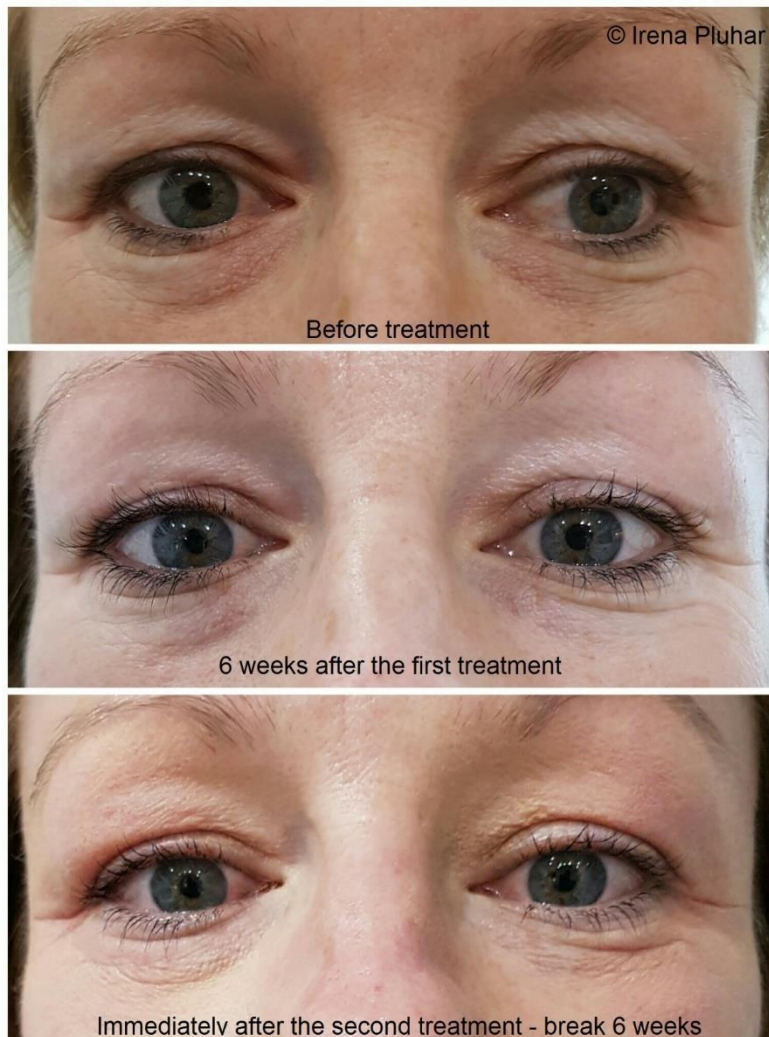Anaesthesia: Local Lidocain-Crème with 23% Lidocain and 3,5 % Tetracaine with occlusion

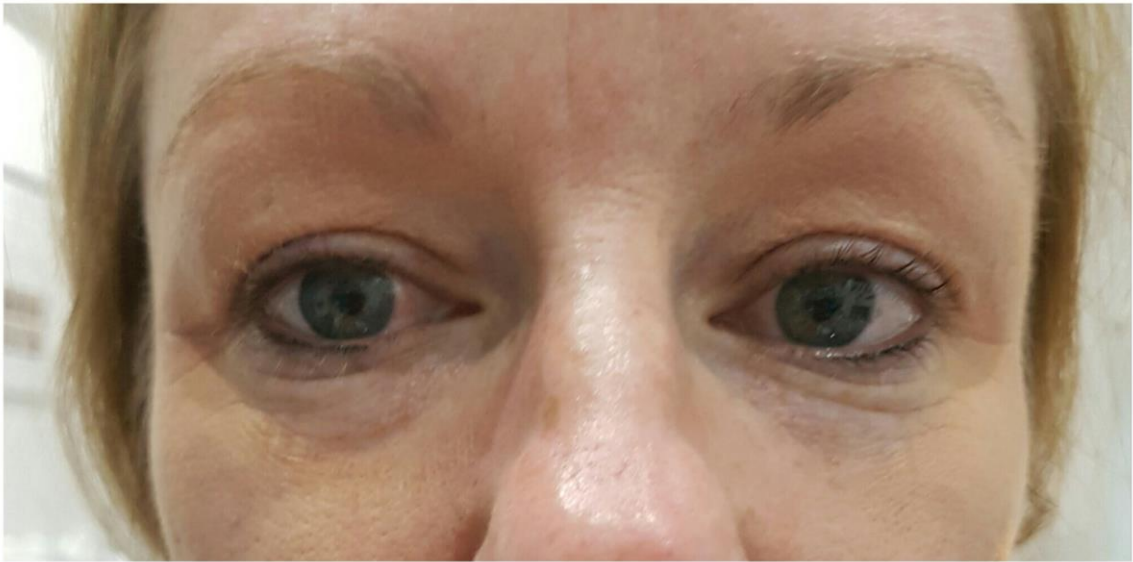
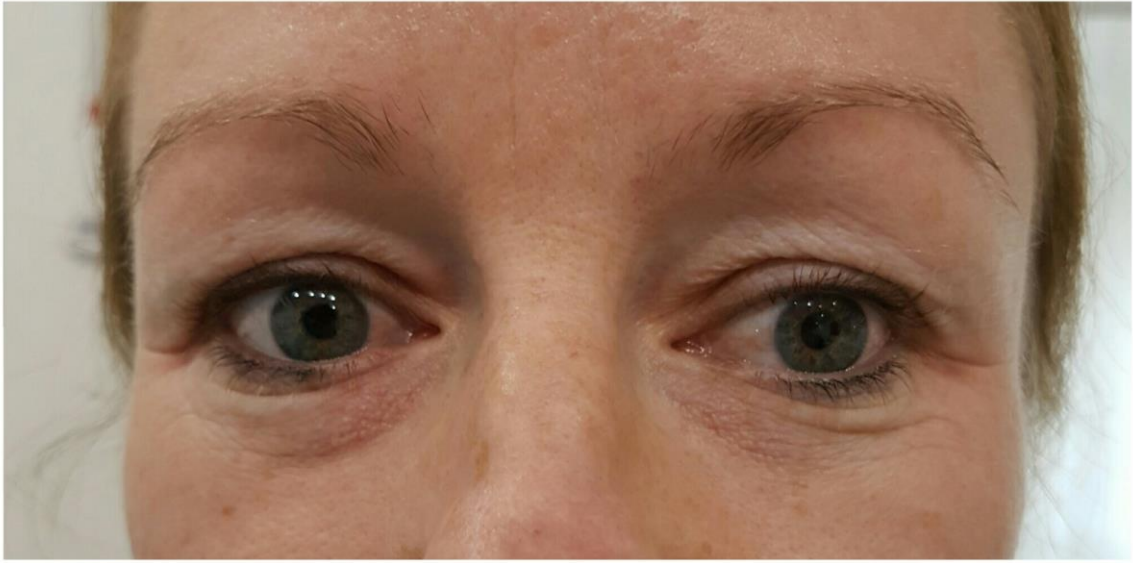The method: 5 minutes of scanning and after dot-by-dot for one upper eyelid

Post treatment: Wash only with nuclear soap, as long as the crust exists. After washing, lightly dab with alcohol-free disinfectant. Daytime Oxygenetyx - special cream with UV protection and healing substances. For the night no care, dry cure. In case of strong sensitivity and redness, antiseptic gel. After heal the crust sun protection

Time of healing: After 2 days crusts, after one week regenerated skin

Side effects: None





Treated area: upper eyelids, both eyes

Patient: Male, 42

Previous undergone aesthetic surgery: None

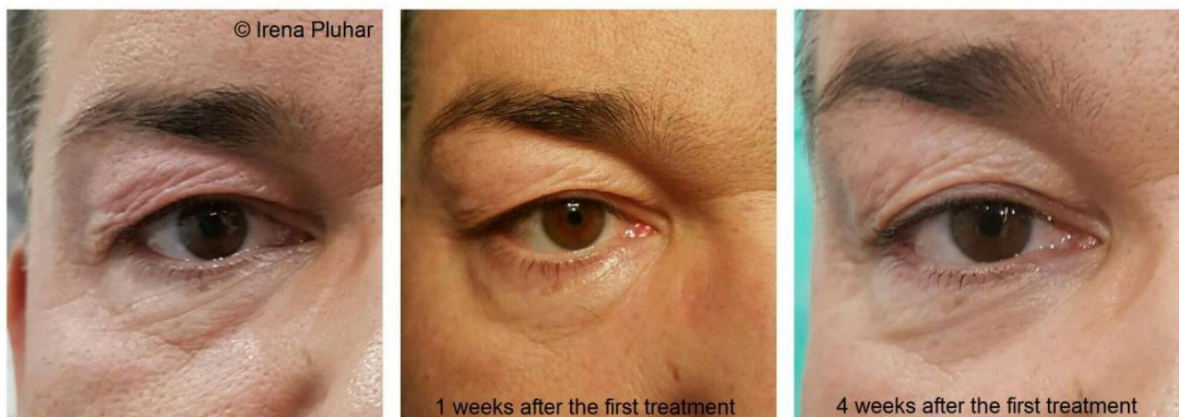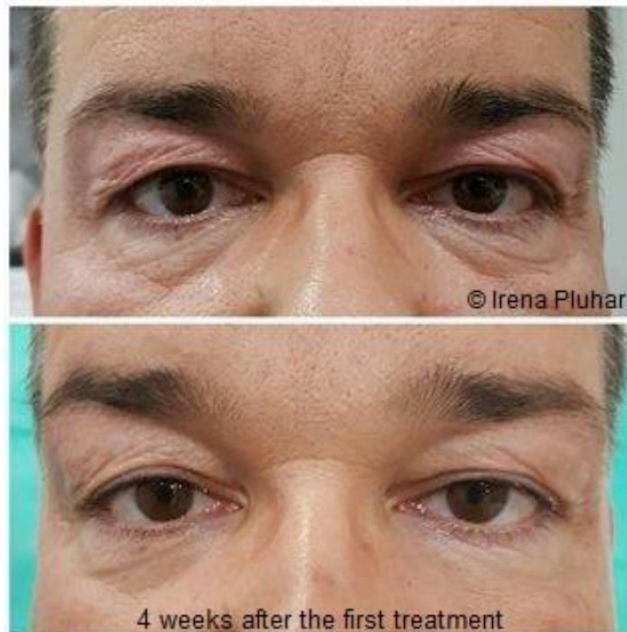Anaesthesia: local Lidocain-Crème with 20% Lidocain and 5 % Tetracaine with occlusion

The method: 5 minutes of scanning and after dot-by-dot for one upper eyelid

Post treatment: Wash only with nuclear soap, as long as the crust exists. After washing, lightly dab with alcohol-free disinfectant. Daytime Oxygenetyx - special cream with UV protection and healing substances. For the night no care, dry cure. In case of strong sensitivity and redness, antiseptic gel. After heal the crust sun protection

Time of healing: after 2 days crusts, after one week regenerated skin

Side effects: None



Treated area: Lower eyelids, lateral folds, both eyes

Patient: Female

Previous undergone aesthetic surgery: None

Anaesthesia: Local Lidocain-Crème with 20% Lidocain, 5 % Tetracaine with occlusion

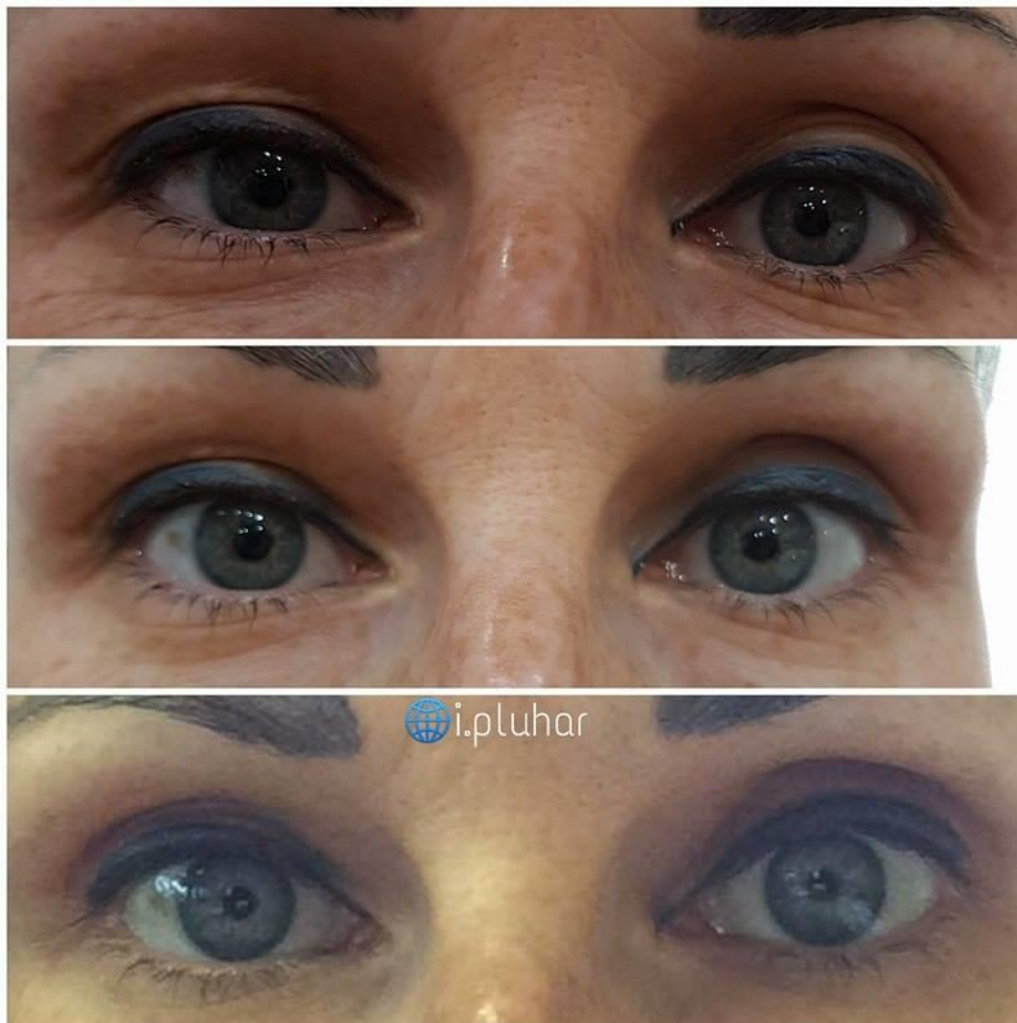The method: 5 minutes of scanning for one lower eyelid, dot-by-dot technique

Post treatment: Wash only with nuclear soap, as long as the crust exists. After washing, lightly dab with alcohol-free disinfectant. Daytime Oxygenetix - special cream with UV protection and healing substances. For the night no care, dry cure. In case of strong sensitivity and redness, antiseptic gel. After heal the crust sun protection and hyaluronic gel

Time of healing: After 2 days crusts, after one week regenerated skin

Side effects: None

Date of photos: Before, Immeadiately after, 16 days after



Treated area: Lower eyelids, lateral folds, both eyes

Patient: Female

Previous undergone aesthetic surgery: None

Anaesthesia: Local Lidocain-Crème with 20% Lidocain, 5 % Tetracaine with occlusion

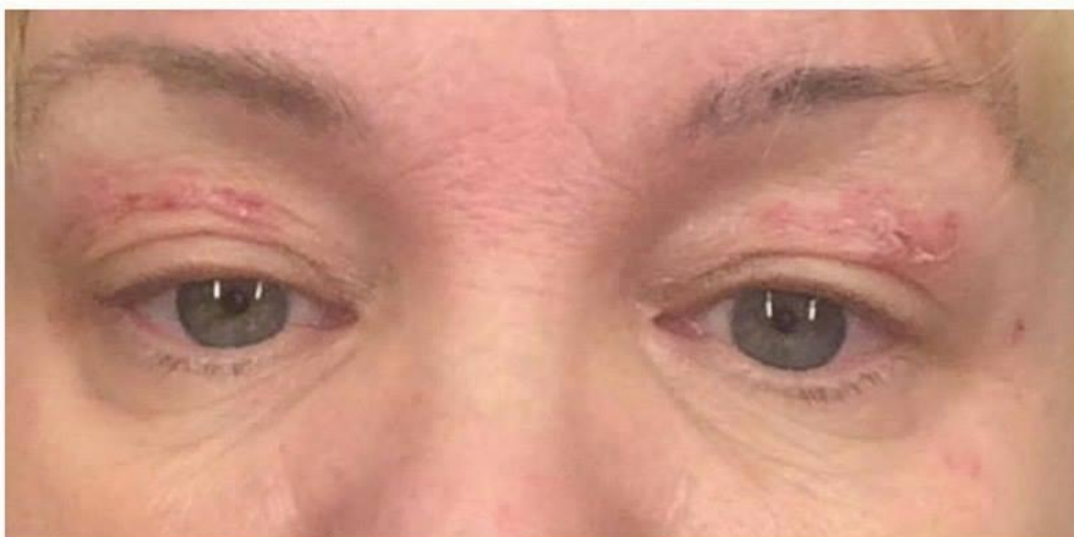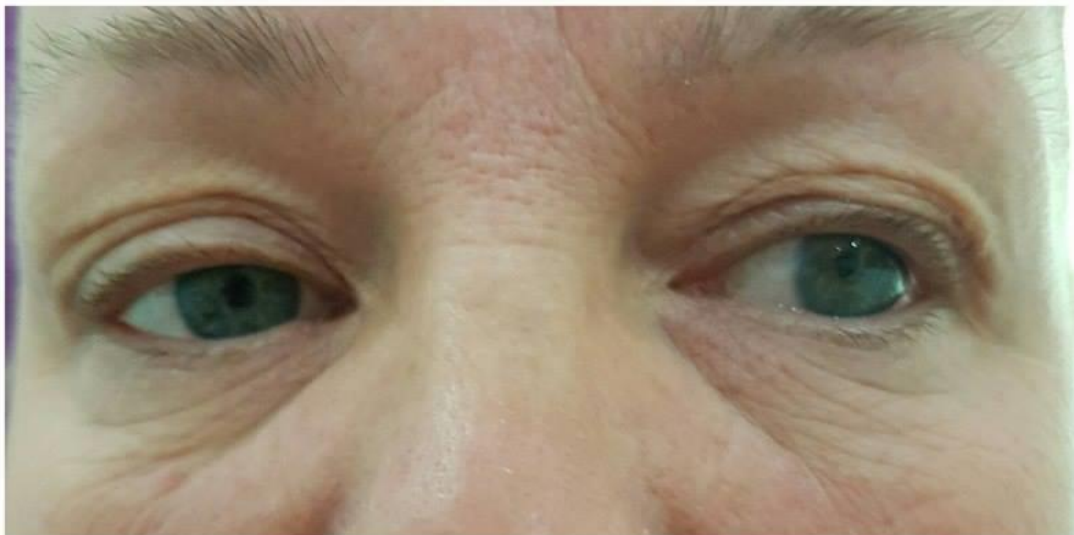The method: 5 minutes of scanning for one lower eyelid, dot-by-dot technique

Post treatment: Wash only with nuclear soap, as long as the crust exists. After washing, lightly dab with alcohol-free disinfectant. Daytime Oxygenetyx - special cream with UV protection and healing substances. For the night no care, dry cure. In case of strong sensitivity and redness, antiseptic gel. After heal the crust sun protection and hyaluronic gel

Time of healing: After 2 days crusts, after one week regenerated skin

Side effects: None

Date of photos: Before, immediately after



Treated area: upper eyelids, both eyes

Patient: female

Previous undergone aesthetic surgery: None

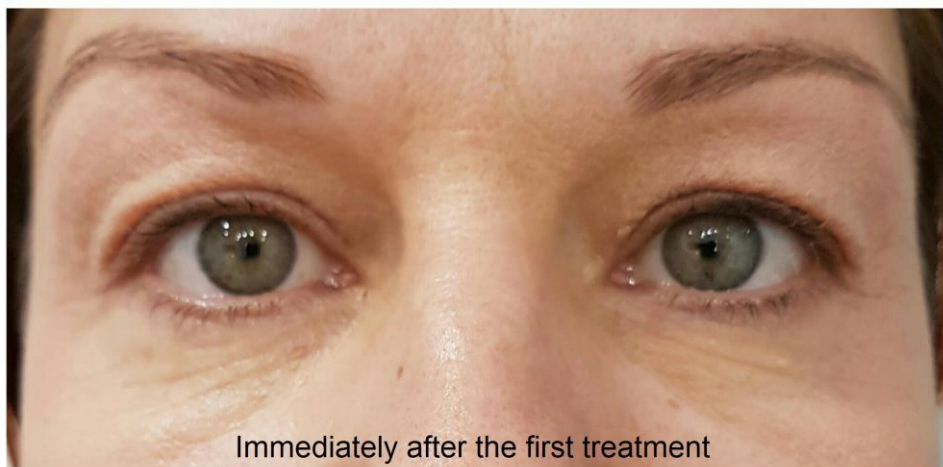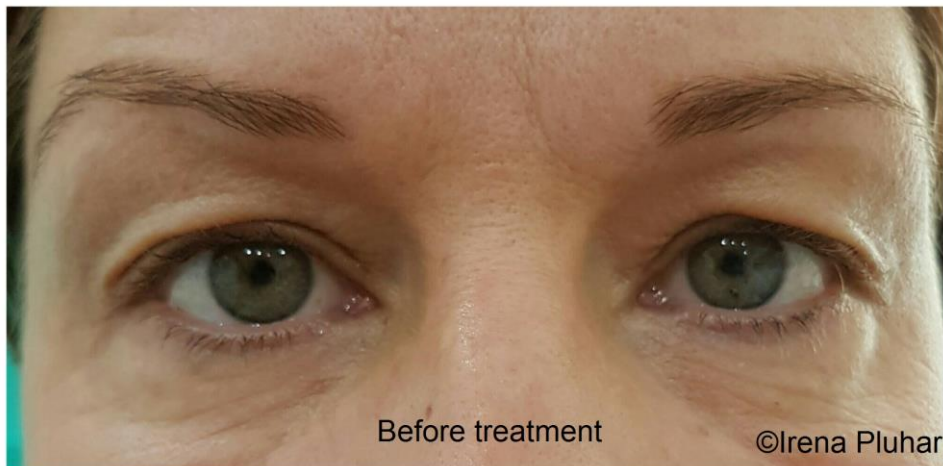
Anaesthesia: local Lidocain-Crème with 20% Lidocain and 5 % Tetracaine with occlusion

The method: intensive scanning

Post treatment: Wash only with nuclear soap, as long as the crust exists. After washing, lightly dab with alcohol-free disinfectant. Daytime Oxygenetyx - special cream with UV protection and healing substances. For the night no care, dry cure. In case of strong sensitivity and redness, antiseptic gel. After heal the crust sun protection

Time of healing: after 2 days crusts, after one week regenerated skin

Side effects: None



Treated area: upper eyelids, both eyes

Patient: female

Previous undergone aesthetic surgery: None

Anaesthesia: local Lidocain-Crème with 20% Lidocain and 5 % Tetracaine with occlusion

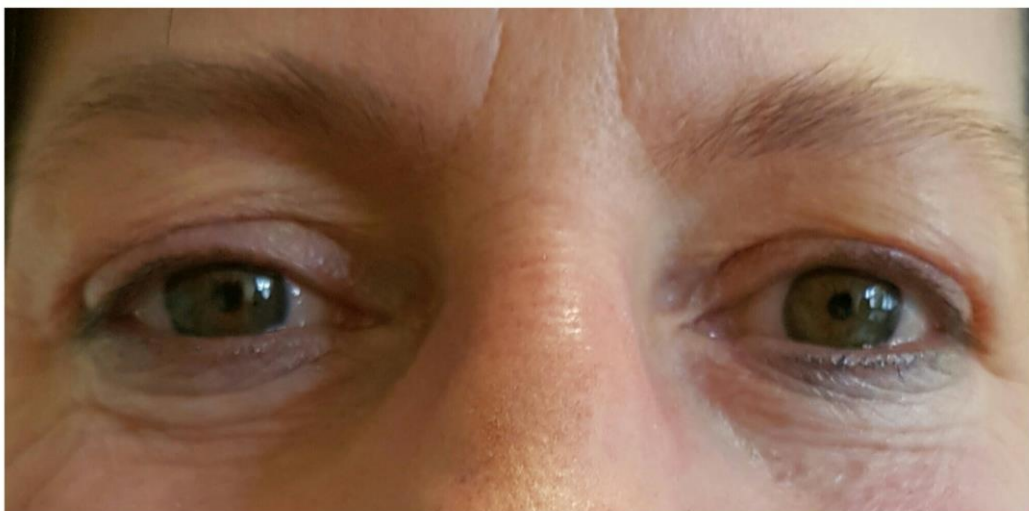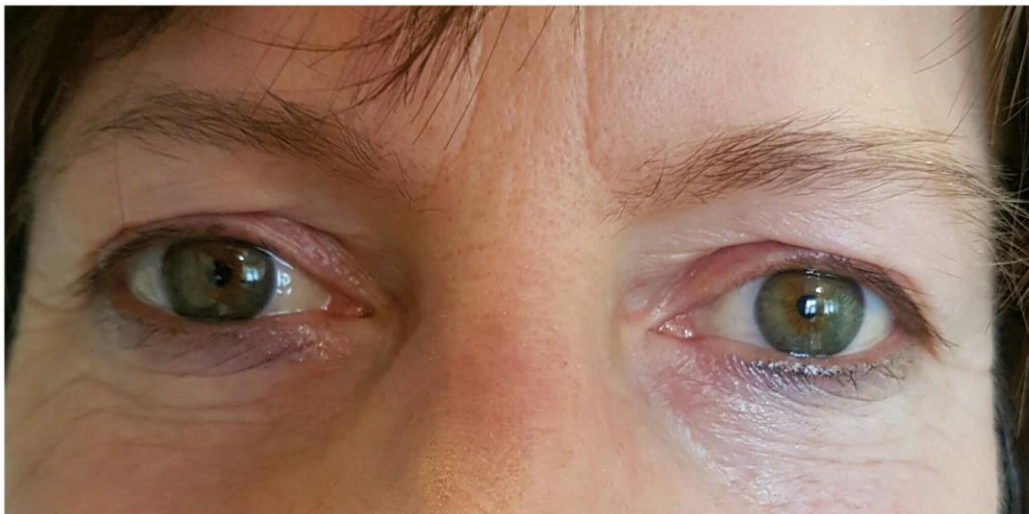The method: intensive scanning

Post treatment: Wash only with nuclear soap, as long as the crust exists. After washing, lightly dab with alcohol-free disinfectant. Daytime Oxygenetix - special cream with UV protection and healing substances. For the night no care, dry cure. In case of strong sensitivity and redness, antiseptic gel. After heal the crust sun protection

Time of healing: after 2 days crusts, after one week regenerated skin

Side effects: None

Date of photos: Before, Week after



Treated area: upper eyelids, both eyes

Patient: female

Previous undergone aesthetic surgery: None

Anaesthesia: local Lidocain-Crème with 20% Lidocain and 5 % Tetracaine with occlusion

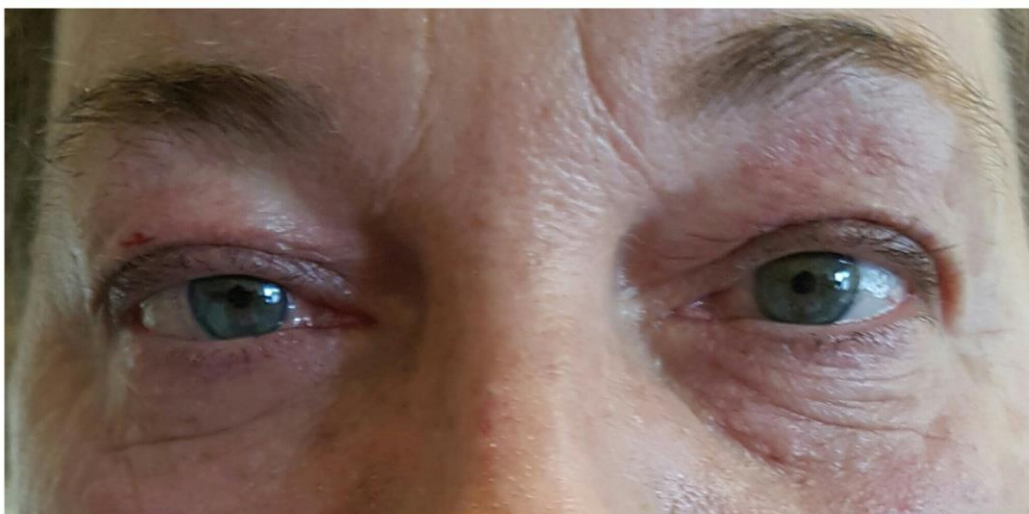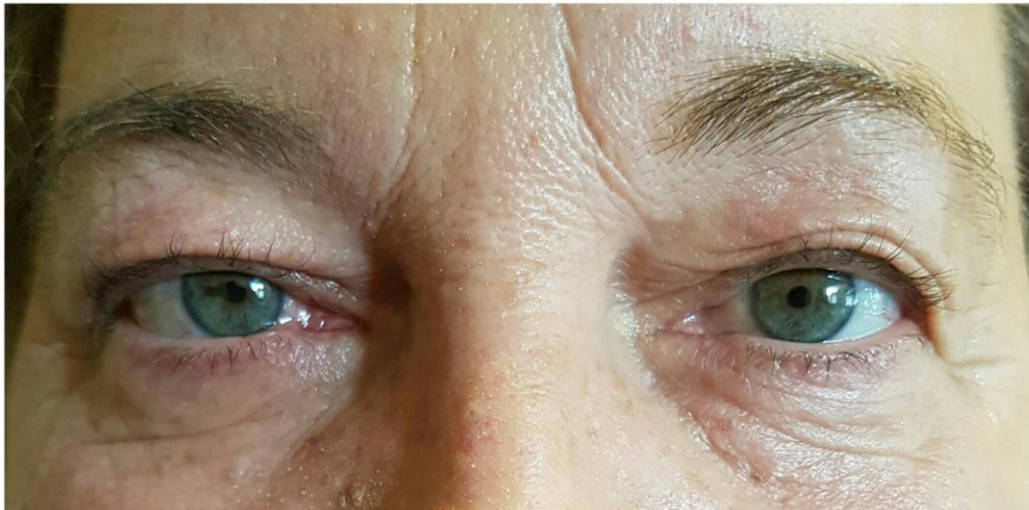The method: intensive scanning

Post treatment: Wash only with nuclear soap, as long as the crust exists. After washing, lightly dab with alcohol-free disinfectant. Daytime Oxygenetyx - special cream with UV protection and healing substances. For the night no care, dry cure. In case of strong sensitivity and redness, antiseptic gel. After heal the crust sun protection

Time of healing: after 2 days crusts, after one week regenerated skin

Side effects: None

Date of photos: Before, Week after



Treated area: upper eyelids, both eyes

Patient: female

Previous undergone aesthetic surgery: None

Anaesthesia: local Lidocain-Crème with 20% Lidocain and 5 % Tetracaine with occlusion

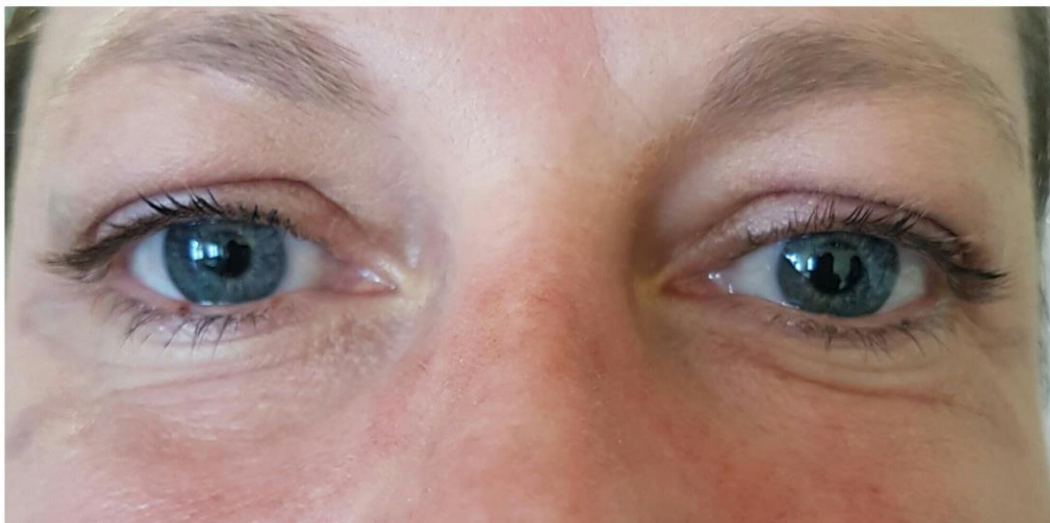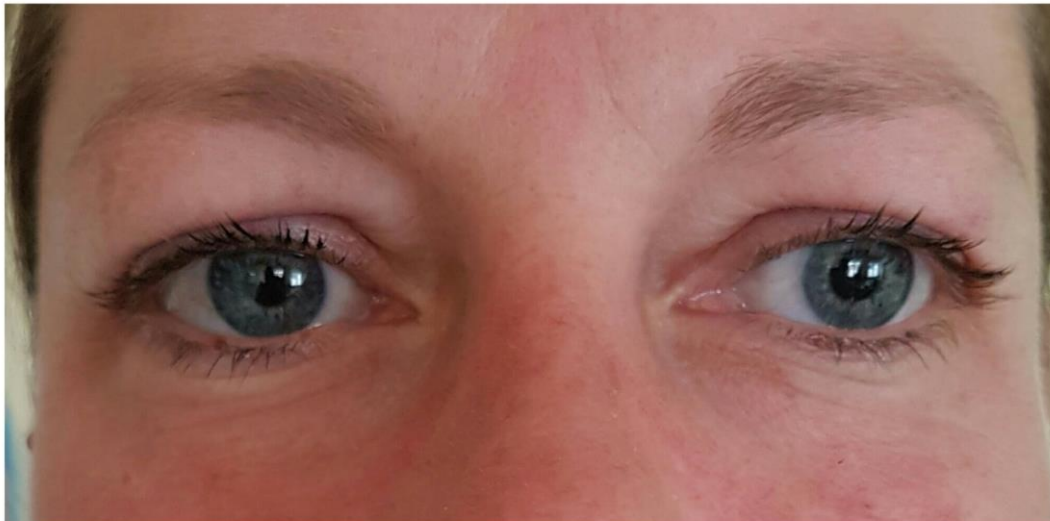The method: intensive scanning

Post treatment: Wash only with nuclear soap, as long as the crust exists. After washing, lightly dab with alcohol-free disinfectant. Daytime Oxygenetyx - special cream with UV protection and healing substances. For the night no care, dry cure. In case of strong sensitivity and redness, antiseptic gel. After heal the crust sun protection

Time of healing: after 2 days crusts, after one week regenerated skin

Side effects: None

Date of photos: Before, Week after



Treated area: upper eyelids, both eyes

Patient: female

Previous undergone aesthetic surgery: None

Anaesthesia: local Lidocain-Crème with 20% Lidocain and 5 % Tetracaine with occlusion

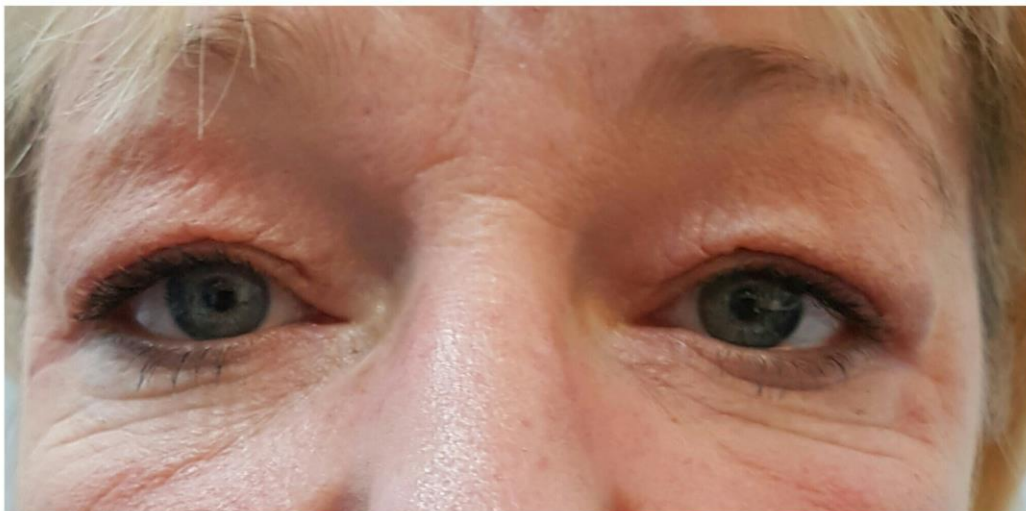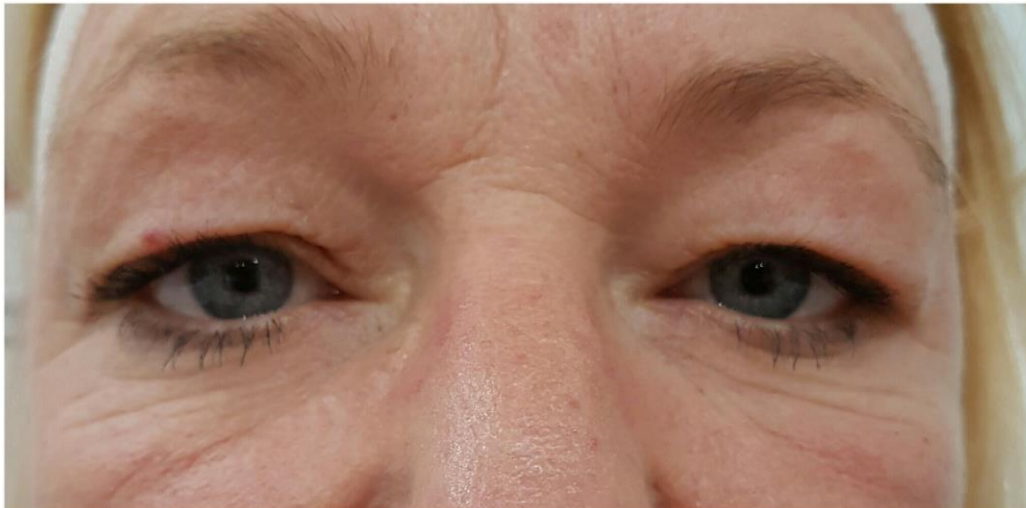The method: intensive scanning

Post treatment: Wash only with nuclear soap, as long as the crust exists. After washing, lightly dab with alcohol-free disinfectant. Daytime Oxygenetyx - special cream with UV protection and healing substances. For the night no care, dry cure. In case of strong sensitivity and redness, antiseptic gel. After heal the crust sun protection

Time of healing: after 2 days crusts, after one week regenerated skin

Side effects: None

Date of photos: Before, Week after



Treated area: upper eyelids, both eyes

Patient: female

Previous undergone aesthetic surgery: None

Anaesthesia: local Lidocain-Crème with 20% Lidocain and 5 % Tetracaine with occlusion

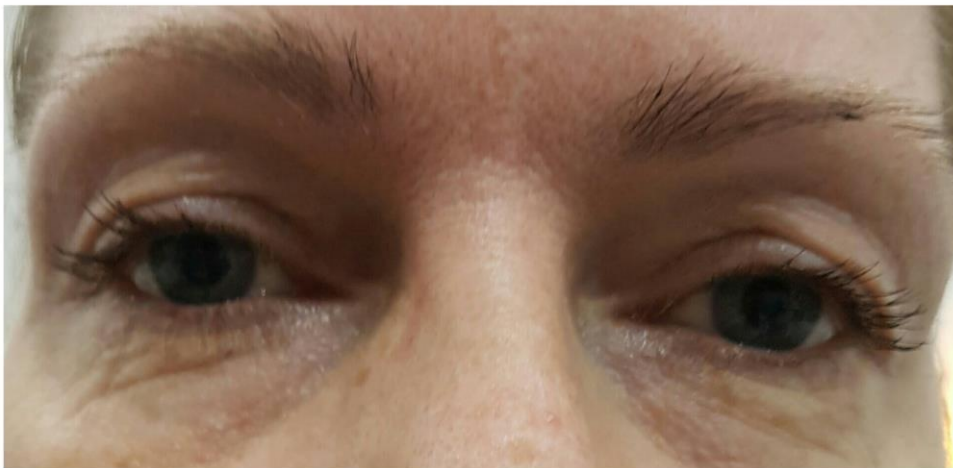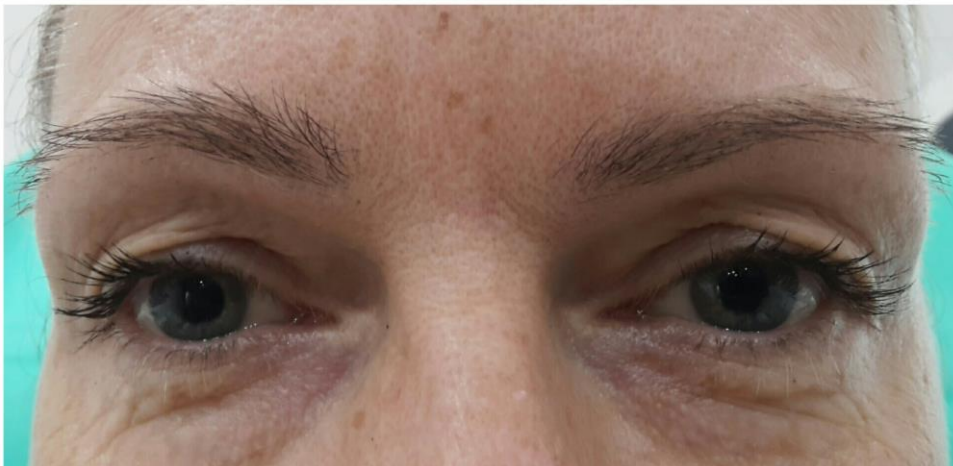The method: intensive scanning

Post treatment: Wash only with nuclear soap, as long as the crust exists. After washing, lightly dab with alcohol-free disinfectant. Daytime Oxygenetix - special cream with UV protection and healing substances. For the night no care, dry cure. In case of strong sensitivity and redness, antiseptic gel. After heal the crust sun protection

Time of healing: after 2 days crusts, after one week regenerated skin

Side effects: None

Date of photos: Before, Week after



Treated area: upper eyelids, both eyes

Patient: female

Previous undergone aesthetic surgery: None

Anaesthesia: local Lidocain-Crème with 20% Lidocain and 5 % Tetracaine with occlusion

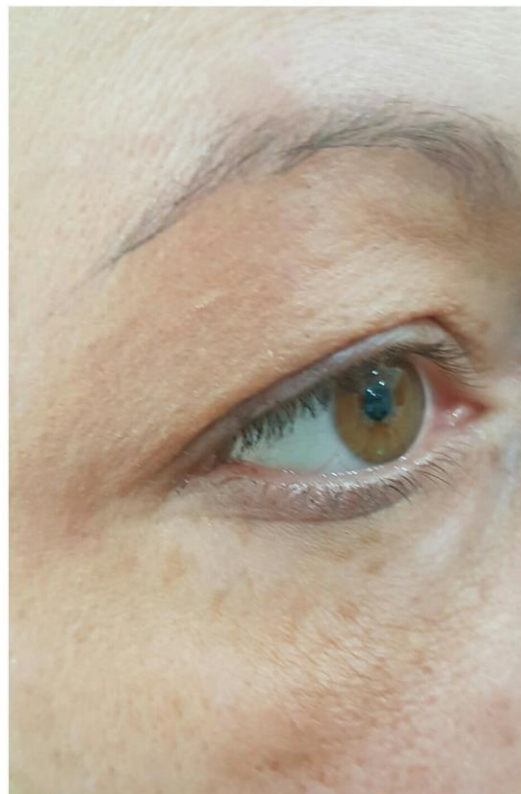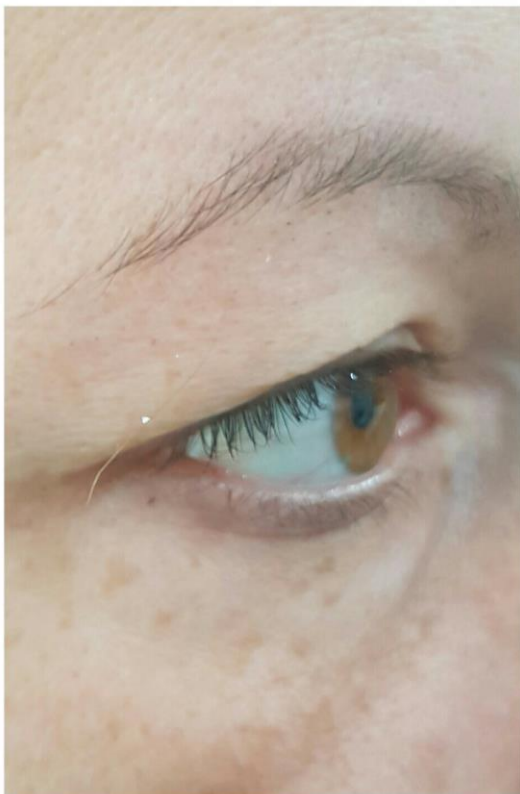The method: intensive scanning

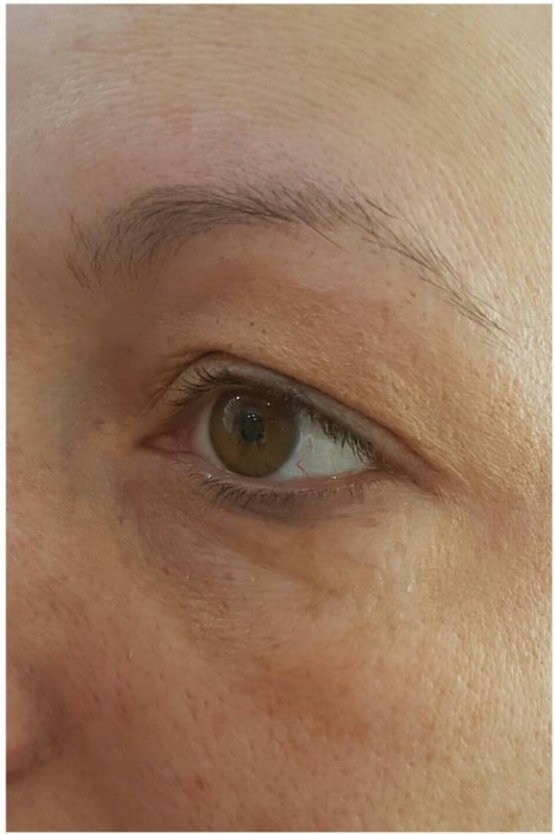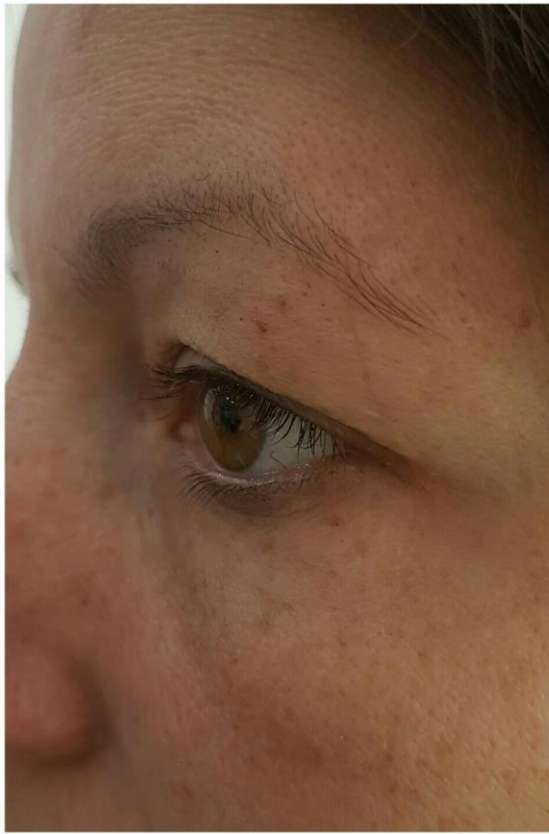Post treatment: Wash only with nuclear soap, as long as the crust exists. After washing, lightly dab with alcohol-free disinfectant. Daytime Oxygenetix - special cream with UV protection and healing substances. For the night no care, dry cure. In case of strong sensitivity and redness, antiseptic gel. After heal the crust sun protection

Time of healing: after 2 days crusts, after one week regenerated skin

Side effects: None

Date of photos: Before, Week after





Treated area: upper eyelids, both eyes

Patient: female

Previous undergone aesthetic surgery: None

Anaesthesia: local Lidocain-Crème with 20% Lidocain and 5 % Tetracaine with occlusion

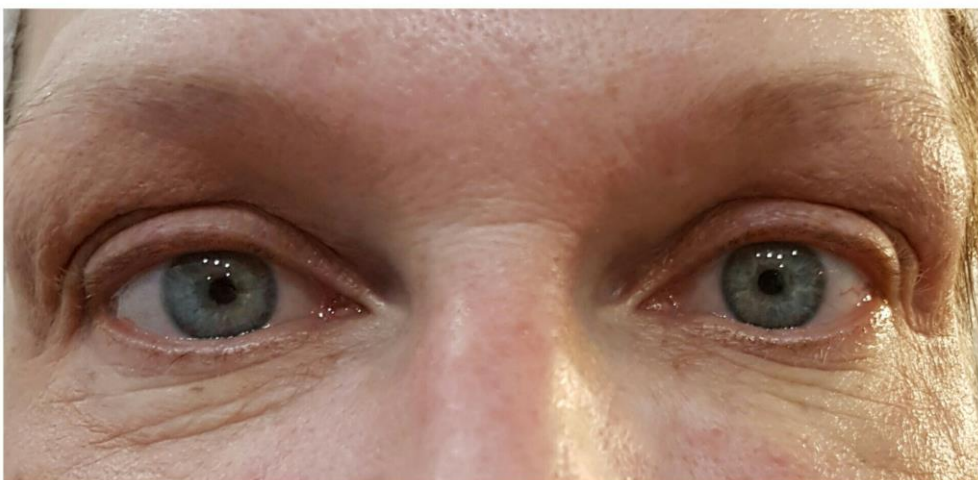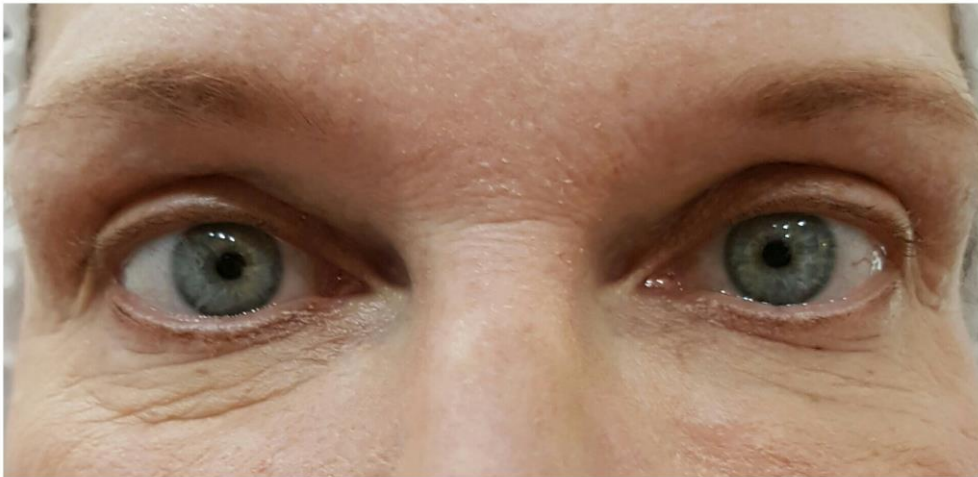The method: intensive scanning

Post treatment: Wash only with nuclear soap, as long as the crust exists. After washing, lightly dab with alcohol-free disinfectant. Daytime Oxygenetyx - special cream with UV protection and healing substances. For the night no care, dry cure. In case of strong sensitivity and redness, antiseptic gel. After heal the crust sun protection

Time of healing: after 2 days crusts, after one week regenerated skin

Side effects: None

Date of photos: Before, immediately after



2.2 Dr. Zeyad Alhamdany, Iraq

Treated area: Around eyes

Patient: 40-60 years

Previous undergone aesthetic surgery: None

Anaesthesia: Lidocaine 2%,approxametly 1 cc for each side around the eye

The method: scanning and dot by dot

Post treatment: some of them used fuciden, some sunblock and eye glasses and some use repairing cream

Time of healing: 2 days

Side effects: reddness,swelling and sometime hyperpigmentation around the eyes.

2.3 Helena Flášarová MD., Dermi Clinic, Brno, Czech Republic

Treated area: upper and lower eyelids, both eyes

Patient: Female, 40

Previous undergone aesthetic surgery: None

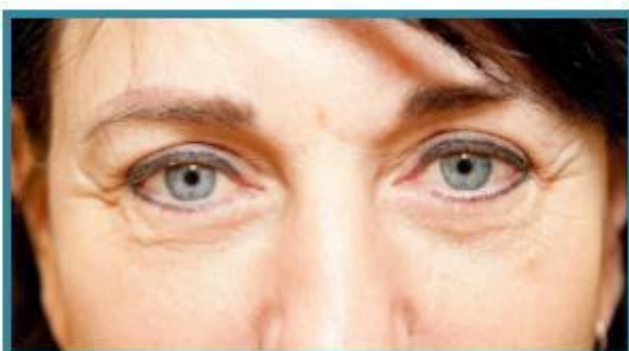Anaesthesia: local injection, Lidocain 5%, 3 ml for one eyelid

The method: 5 minutes of scanning and after dot-by-dot for one upper eyelid, 5 minutes of scanning for one lower eyelid

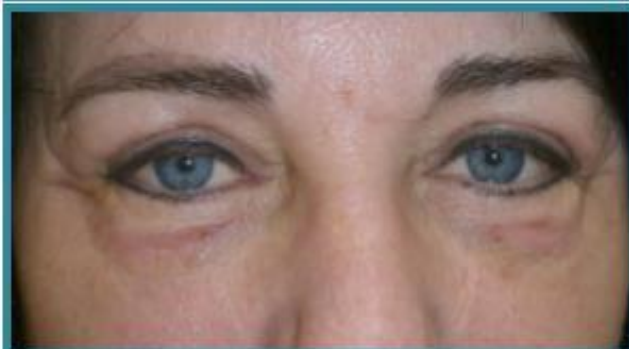Post treatment: regenerating serum with HA (twice a day) for 5 days, sun protection for 1 month (glasses, SPF 50+)

Time of healing: after 3 days crusts, after one week regenerated skin

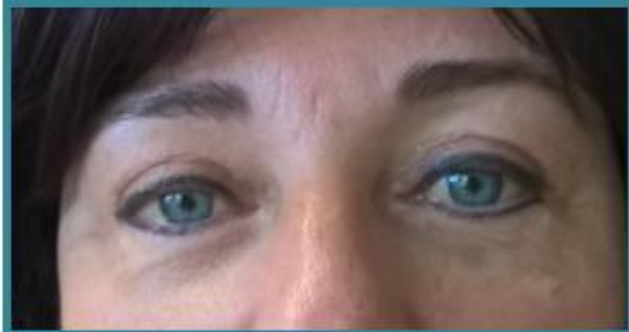Side effects: None



before



after 10 days



after 3 months

Treated area: upper and lower eyelids, both eyes

Patient: Female, 63

Previous undergone aesthetic surgery: None

Anaesthesia: local injection, Lidocain 5%, 3 ml for one eyelid

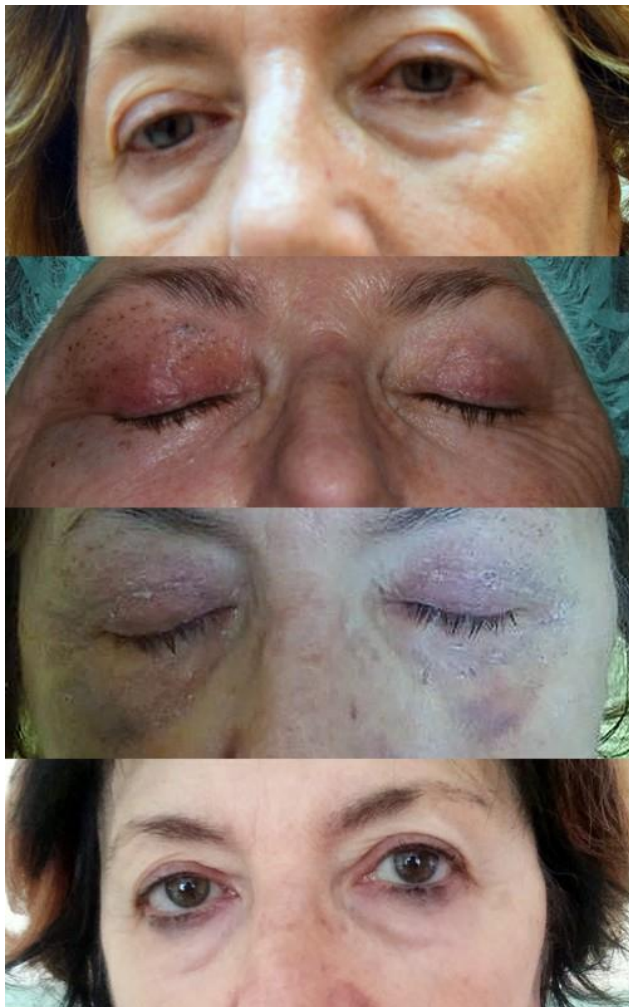The method: 5 minutes of scanning and after dot-by-dot for one upper eyelid, 5 minutes of scanning for one lower eyelid

Post treatment: sun protection (glasses, SPF 50+), application of Jett LiftVital serum for one month

Time of healing: 10 days

Side effects: small hematomas due to injection of the anaesthesia

The date of photos: Before, Immediately after, 3 days after, 2 months after



Treated area: upper and lower eyelids, both eyes

Patient: Female, 40

Previous undergone aesthetic surgery: None

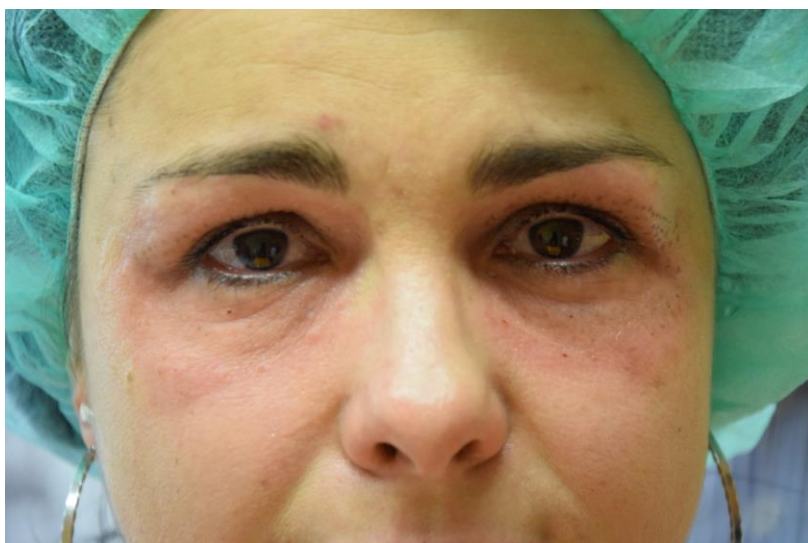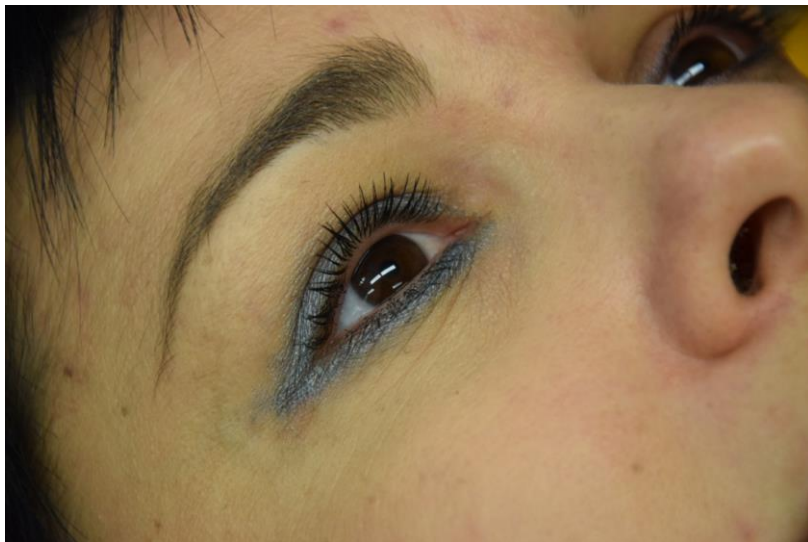Anaesthesia: local injection, Lidocain 5%, 3 ml for one eyelid

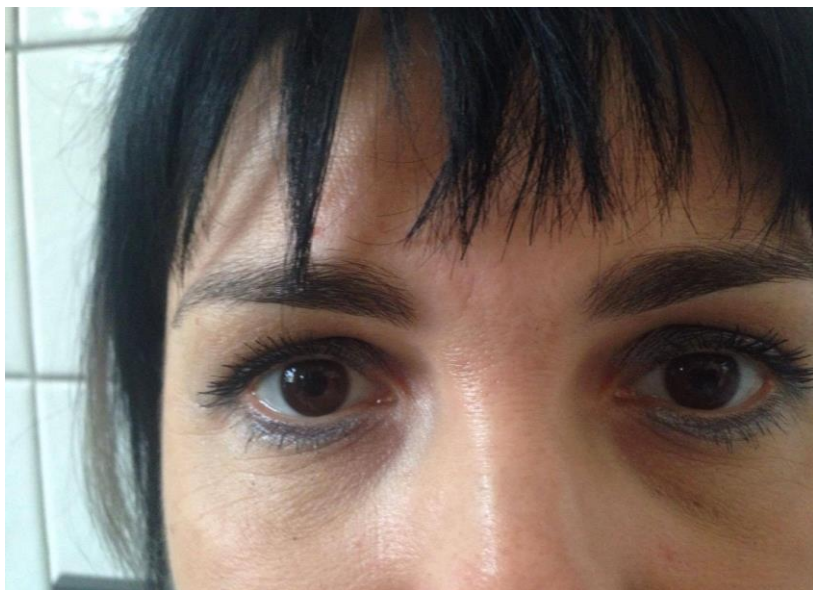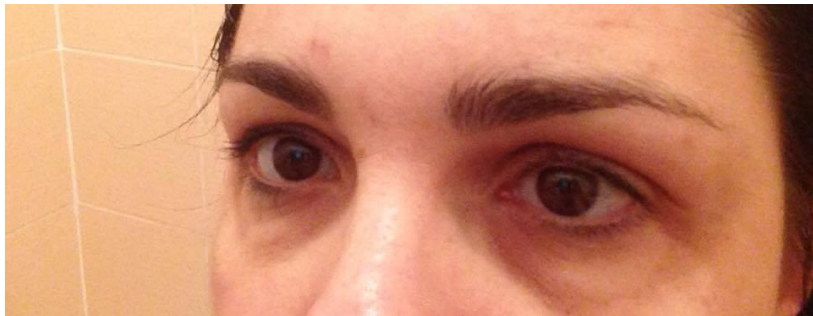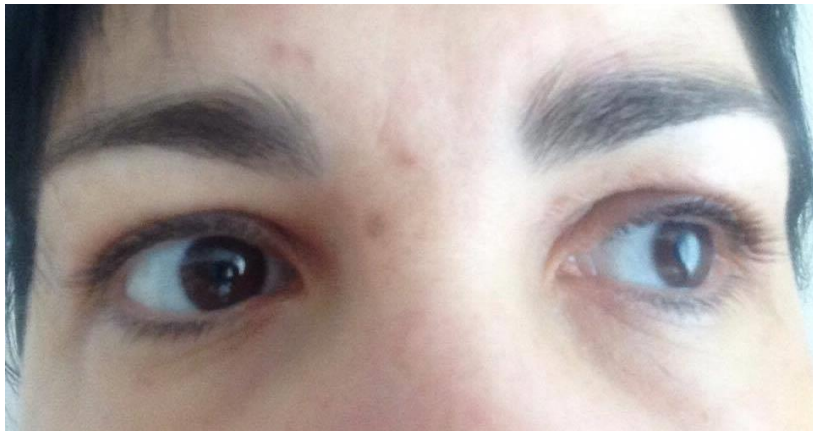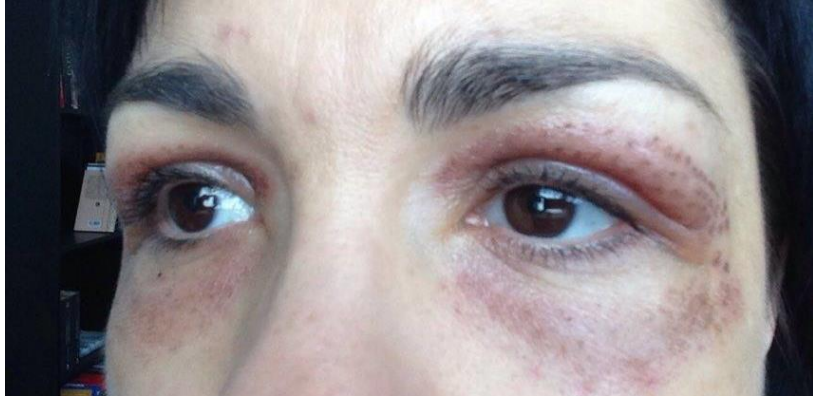The method: 5 minutes of scanning and after dot-by-dot for one upper eyelid, 5 minutes of scanning for one lower eyelid

Post treatment: regenerating serum with HA (twice a day) for 5 days, sun protection for 1 month (glasses, SPF 50+)

Time of healing: after 3 days crusts, after one week regenerated skin

The date of photos: Before, Immediately after, 2 days after, 5 days after, 14 days after, 3 months after





Treated area: upper and lower eyelids, both eyes

Patient: Female, 46

Previous undergone aesthetic surgery: None

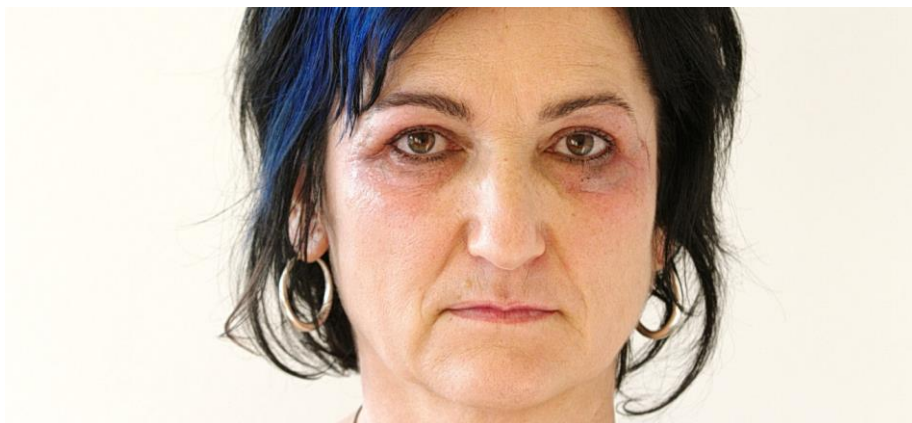Anaesthesia: local injection, Lidocain 5%, 3 ml for one eyelid

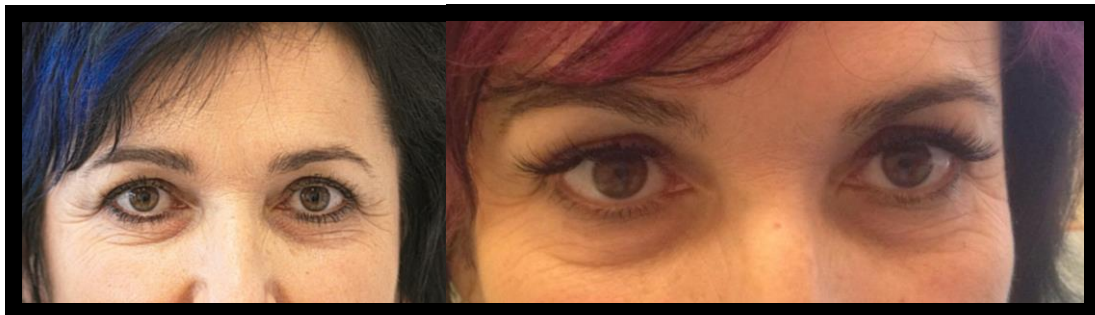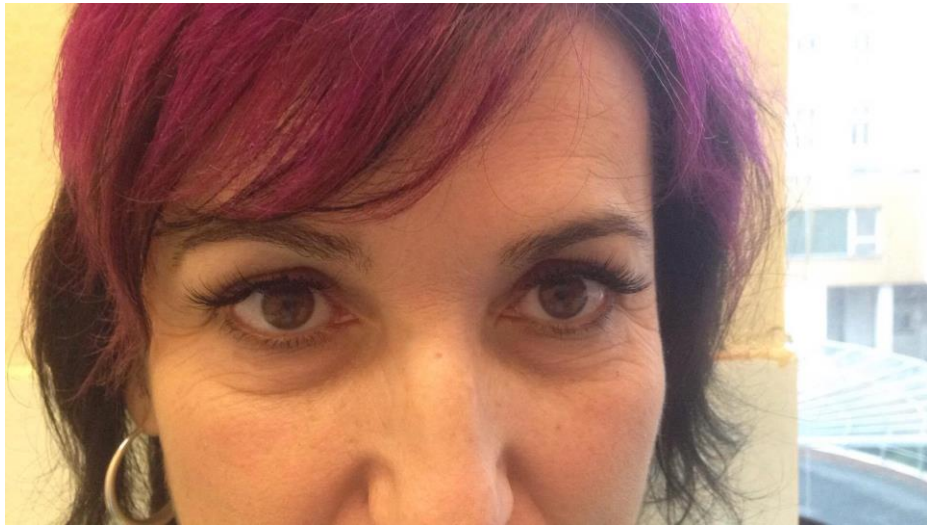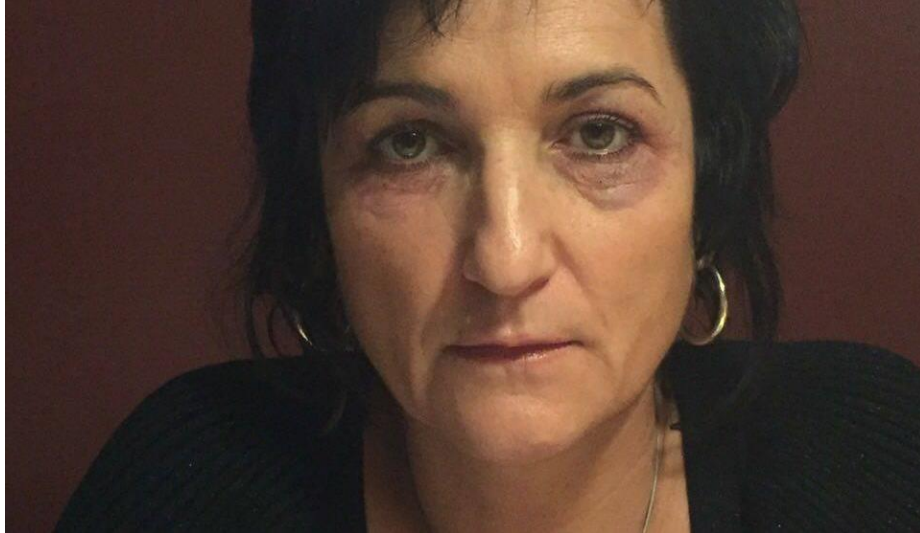The method: 5 minutes of scanning and after dot-by-dot for one upper eyelid, 5 minutes of scanning for one lower eyelid

Post treatment: regenerating serum with HA (twice a day) for 5 days, sun protection for 1 month (glasses, SPF 50+)

Time of healing: after 3 days crusts, after one week regenerated skin

The date of photos: Before, Immediately after, After 1 month





BEFORE

AFTER

Treated area: upper and lower eyelids, both eyes

Patient: Female, 51

Previous undergone aesthetic surgery: Surgical blepharoplasty before 2 years

Anaesthesia: local injection, Lidocain 5%, 3 ml for one eyelid

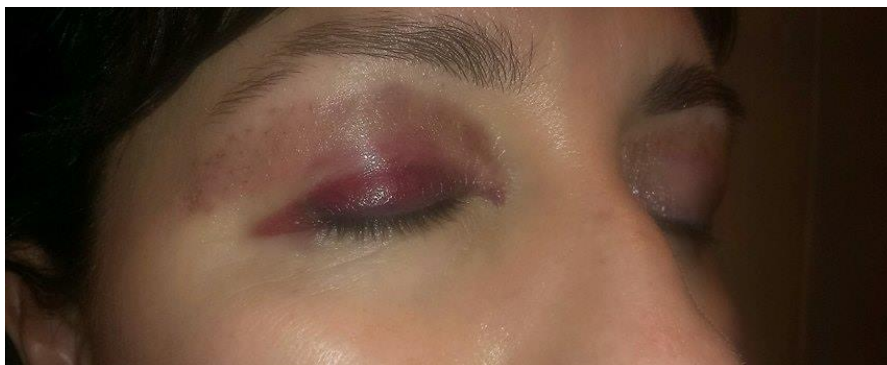The method: 5 minutes of scanning and after dot-by-dot for one upper eyelid, 5 minutes of scanning for one lower eyelid

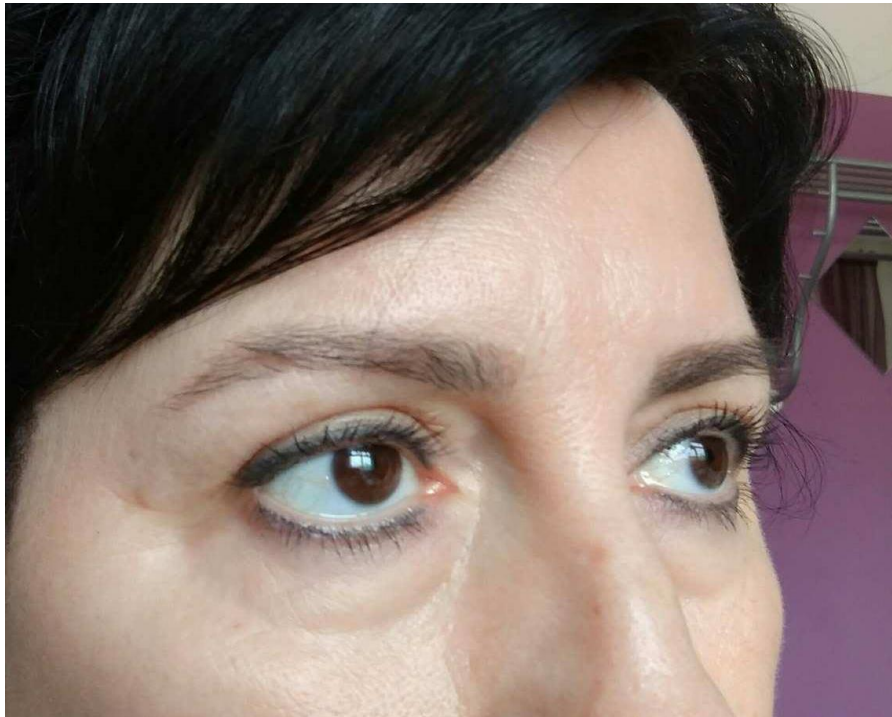
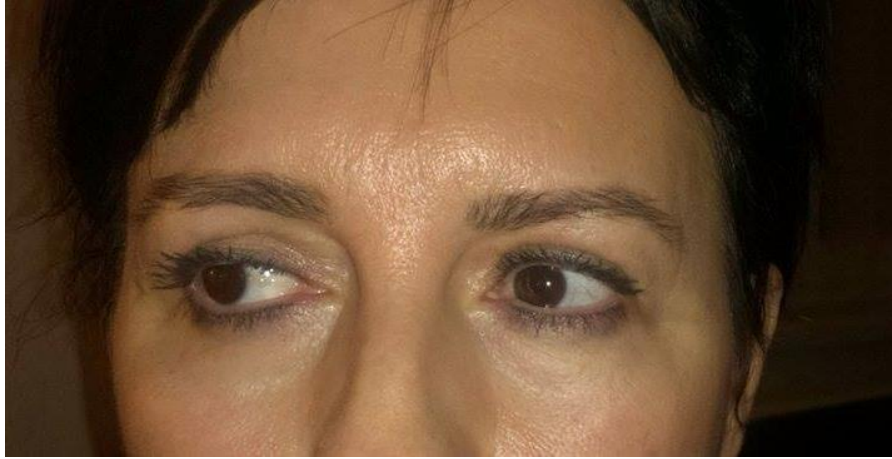Post treatment: regenerating serum with HA (twice a day) for 5 days, sun protection for 1 month (glasses, SPF 50+)

Time of healing: after 3 days crusts, after one week regenerated skin

Side effects: haematoma for one week

The date of photos: Before, Next day, 14 days after, 3 months after





Treated area: upper and lower eyelids, both eyes

Patient: Female, 54

Previous undergone aesthetic surgery: none

Anaesthesia: local injection, Lidocain 5%, 3 ml for one eyelid

The method: 5 minutes of scanning and after dot-by-dot for one upper eyelid, 5 minutes of scanning for one lower eyelid

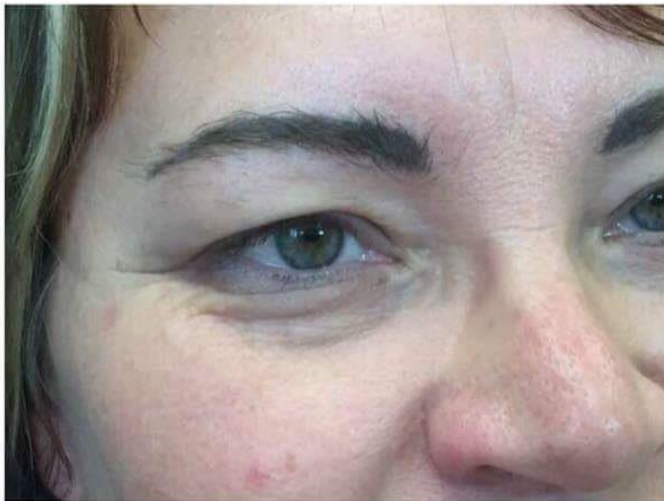Post treatment: regenerating serum with HA (twice a day) for 5 days, sun protection for 1 month (glasses, SPF 50+)

Time of healing: after 3 days crusts, after one week regenerated skin

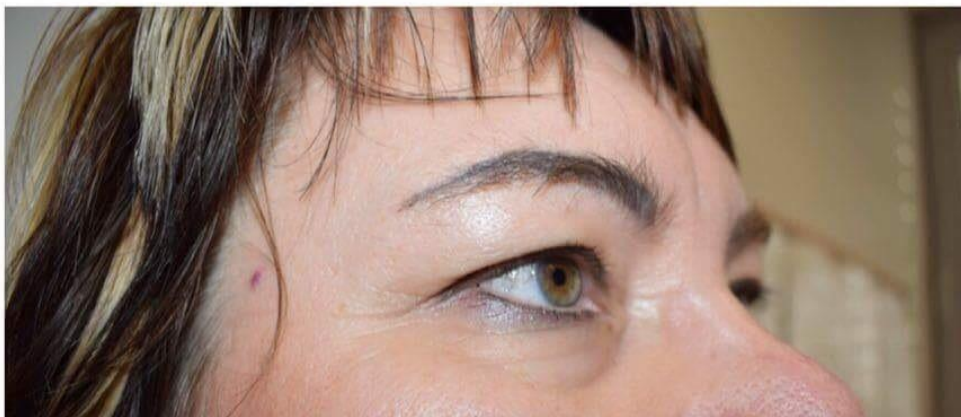Side effects: none

The date of photos: Before, 3 months after

Před zákrokem (54 let)



3měsíce po zákroku



Treated area: upper and lower eyelids, both eyes

Patient: Female

Previous undergone aesthetic surgery: none

Anaesthesia: local injection, Lidocain 5%, 3 ml for one eyelid

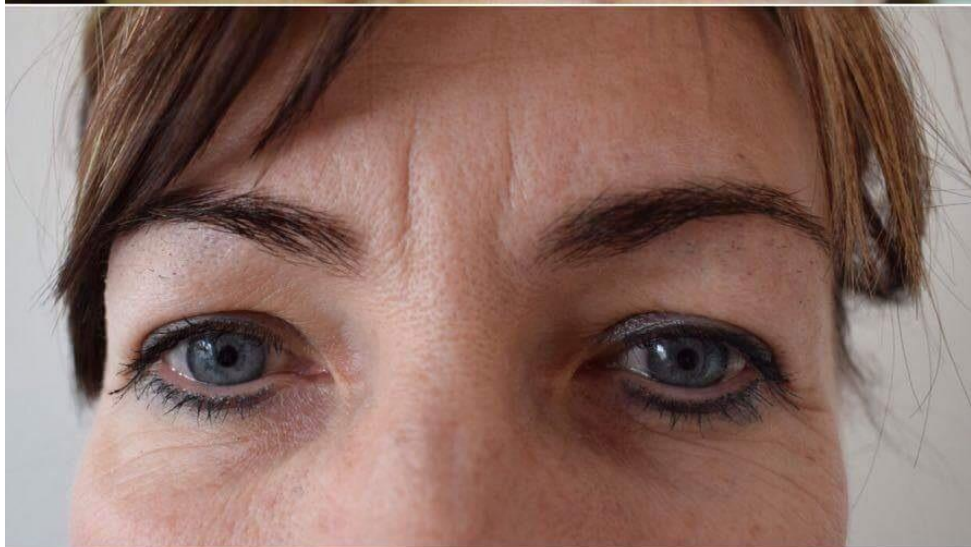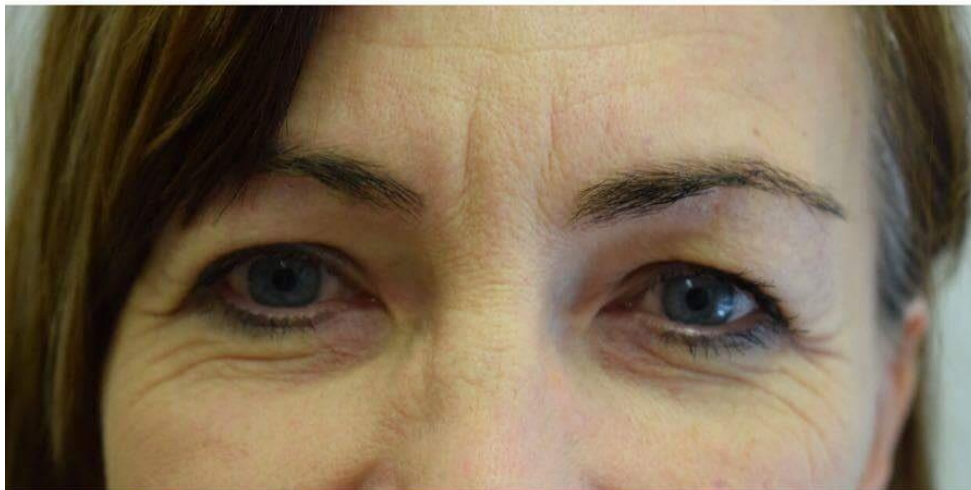The method: 5 minutes of scanning and after dot-by-dot for one upper eyelid, 5 minutes of scanning for one lower eyelid

Post treatment: regenerating serum with HA (twice a day) for 5 days, sun protection for 1 month (glasses, SPF 50+)

Time of healing: after 3 days crusts, after one week regenerated skin

Side effects: none

The date of photos: Before, 3 months after



Treated area: upper and lower eyelids, both eyes

Patient: Female

Previous undergone aesthetic surgery: none

Anaesthesia: local injection, Lidocain 5%, 3 ml for one eyelid

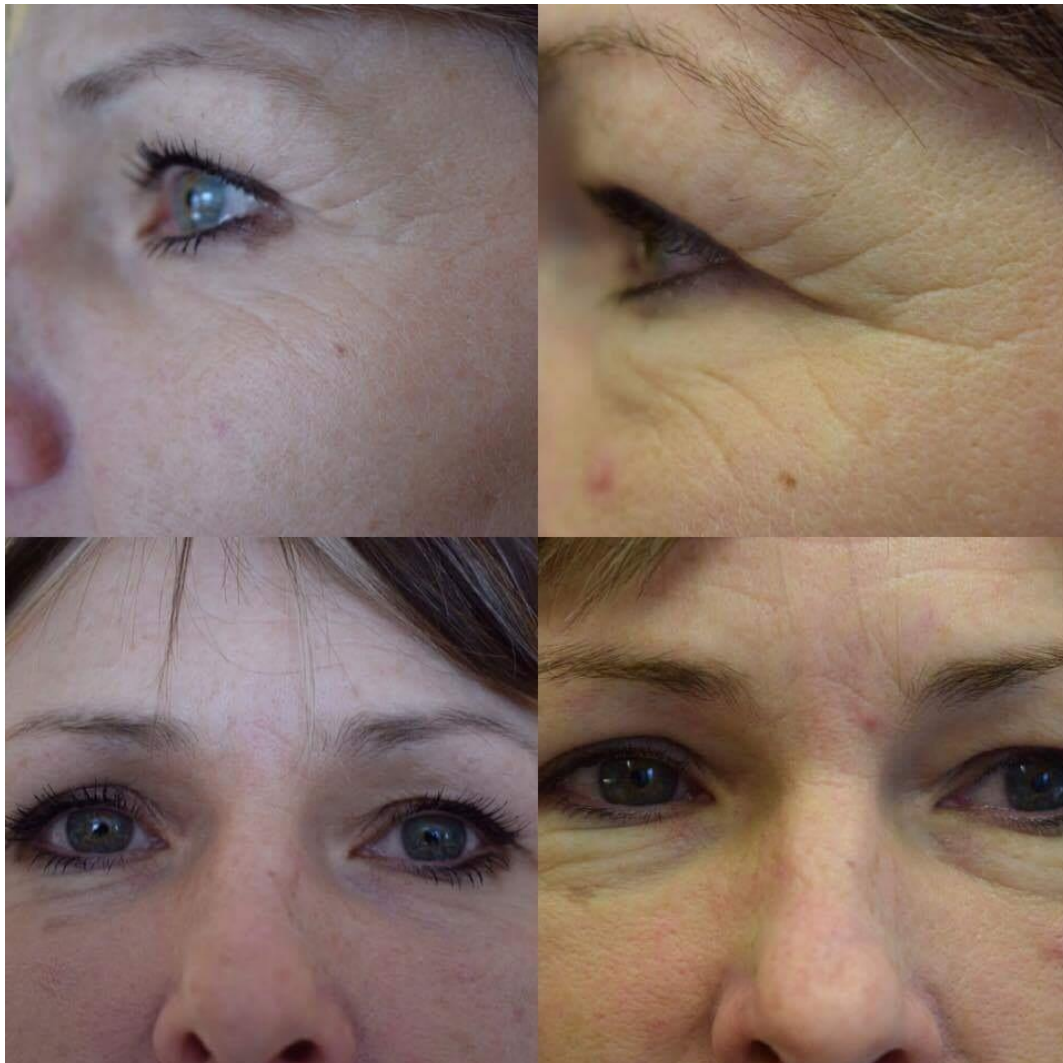The method: 5 minutes of scanning and after dot-by-dot for one upper eyelid, 5 minutes of scanning for one lower eyelid

Post treatment: regenerating serum with HA (twice a day) for 5 days, sun protection for 1 month (glasses, SPF 50+)

Time of healing: after 3 days crusts, after one week regenerated skin

Side effects: none

The date of photos: Before, 3 months after



Treated area: upper and lower eyelids, both eyes

Patient: Female

Previous undergone aesthetic surgery: none

Anaesthesia: local injection, Lidocain 5%, 3 ml for one eyelid

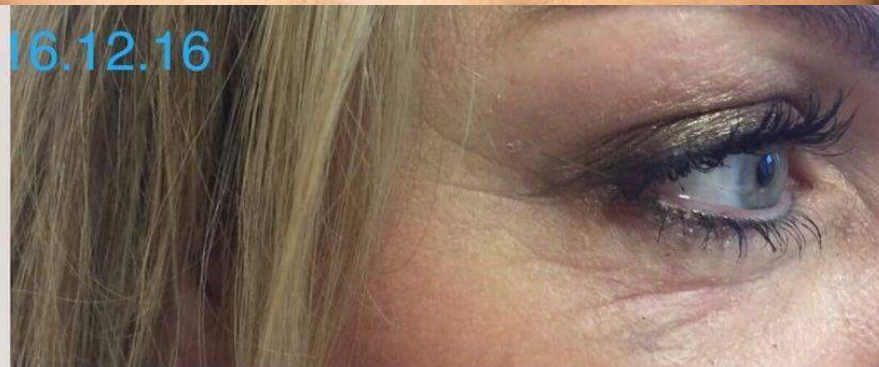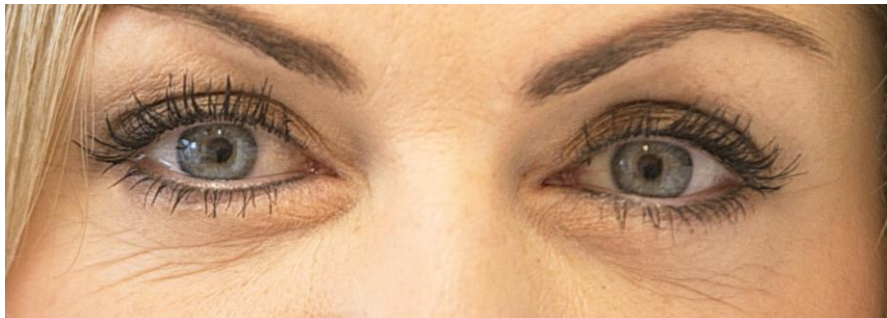The method: 5 minutes of scanning and after dot-by-dot for one upper eyelid, 5 minutes of scanning for one lower eyelid

Post treatment: regenerating serum with HA (twice a day) for 5 days, sun protection for 1 month (glasses, SPF 50+)

Time of healing: after 3 days crusts, after one week regenerated skin

Side effects: none

The date of photos: Before, after six days



2.4 BIA

Treated area: upper eyelids

Patient: Female

Previous undergone aesthetic surgery: None

Anaesthesia: Lidocaine Cream 10.6% 30 mins

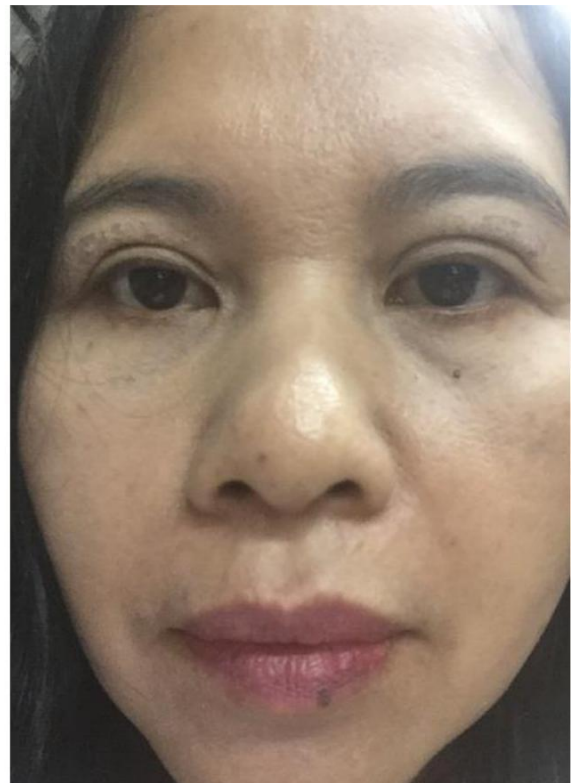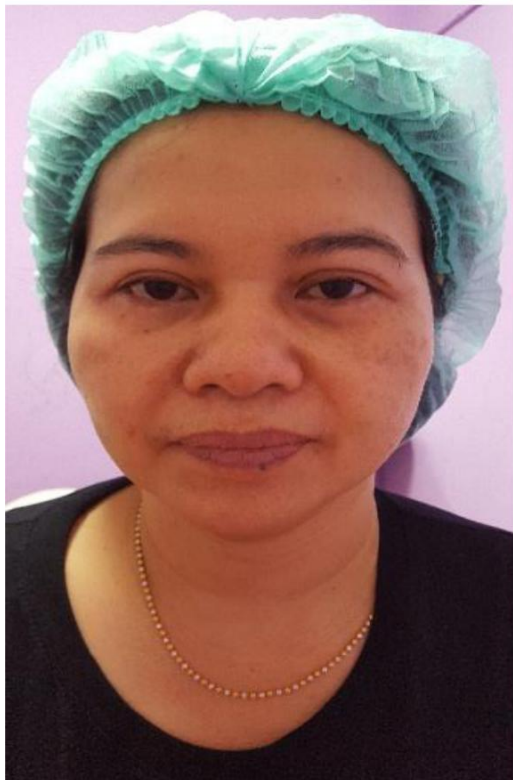The method: Scanning until erythema : power 6

Post treatment TA Cream 0.02%

Time of healing: 3-4 days

Side effects: None

Date of photos: 10.2.2017, 14.2.2017



Treated area: upper eyelids

Patient: Female

Previous undergone aesthetic surgery: None

Anaesthesia: Lidocaine Cream 10.6% 30 mins

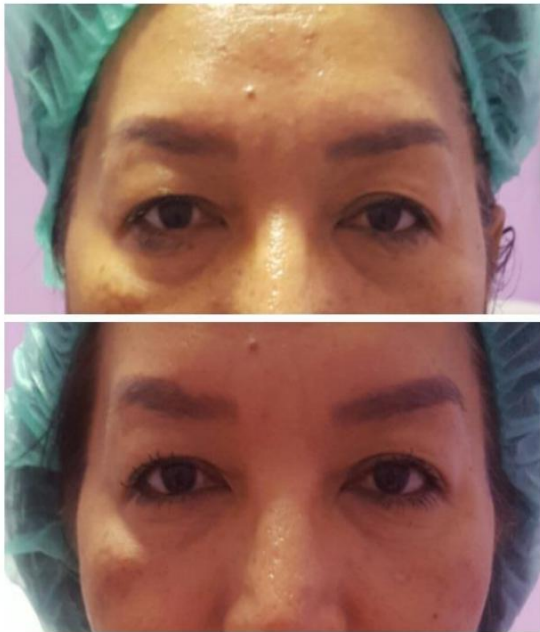The method: Scanning until erythema : power 6

Post treatment TA Cream 0.02%

Time of healing: 3-4 days

Side effects: None

Date of photos: 23.1.2017, 4.2.2017, 14.2.2017



2.5 Diana Petrova, Salon "Effect", Sofia, Bulgaria

Treated area: Face, neck and neck area

Patient: Female, 60

Previous undergone aesthetic surgery: None

Anaesthesia: -

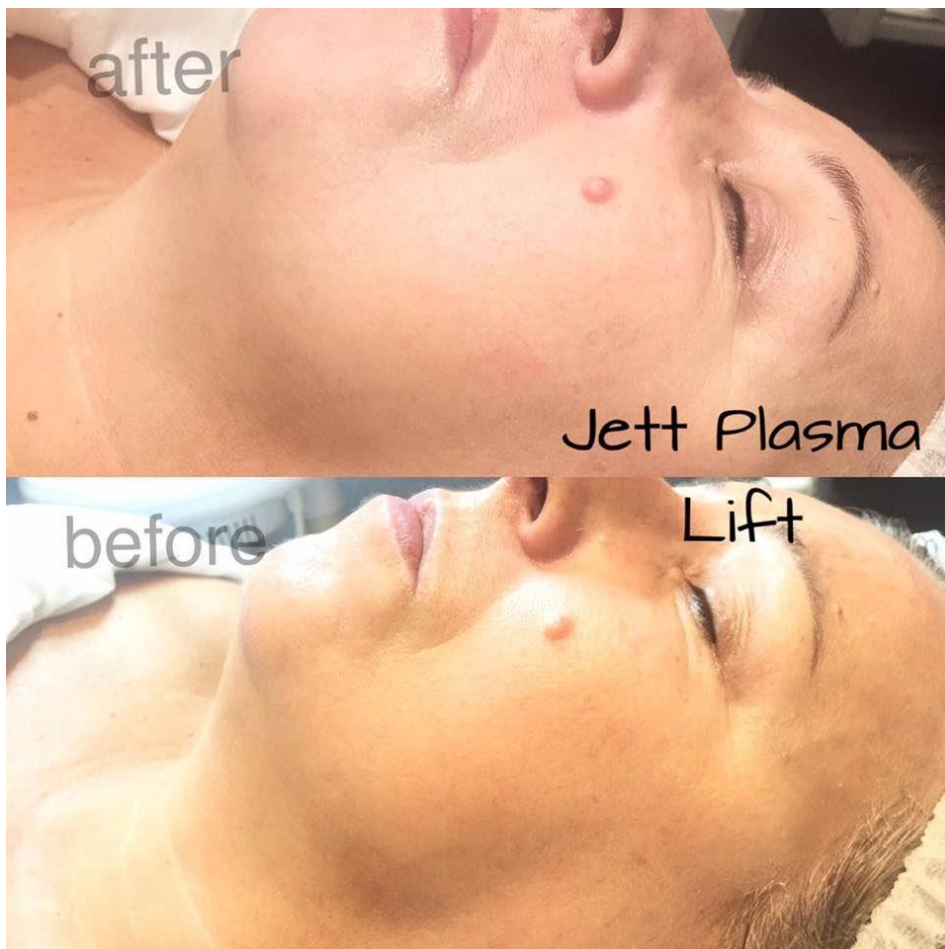The method: Beauty tip with contact gel; Treatment of the right half of the face

Post treatment home care

Time of healing: None

Side effects: None

Results: Pad, lifting and firming facial contours, relief of wrinkles. Visibly retraction of a double chin.



Treated area: inner thighs - old capillaries

Patient: Female, 50

Previous undergone aesthetic surgery: None

Anaesthesia: -

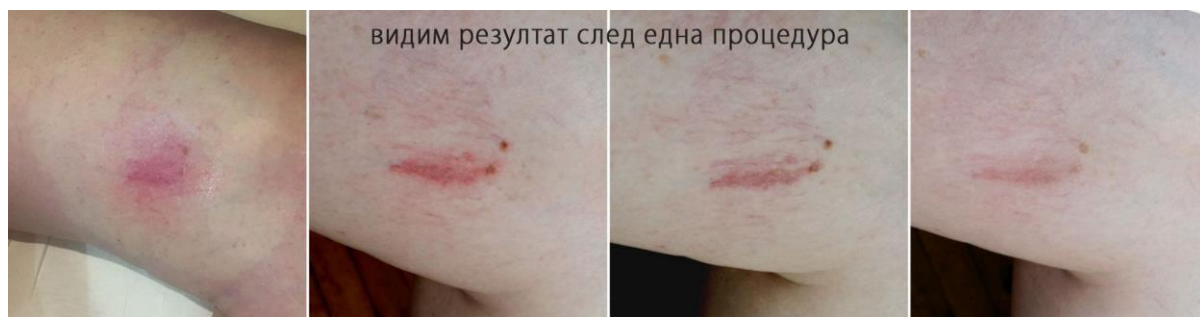The method: gold tip

Post treatment: home care

Time of healing: 2 weeks

Side effects: slight swelling and redness

Results: visibly gathering the capillaries



Treated area: Right half of the face, neck and neck area

Patient: Female, 51

Previous undergone aesthetic surgery: None

Anaesthesia: -

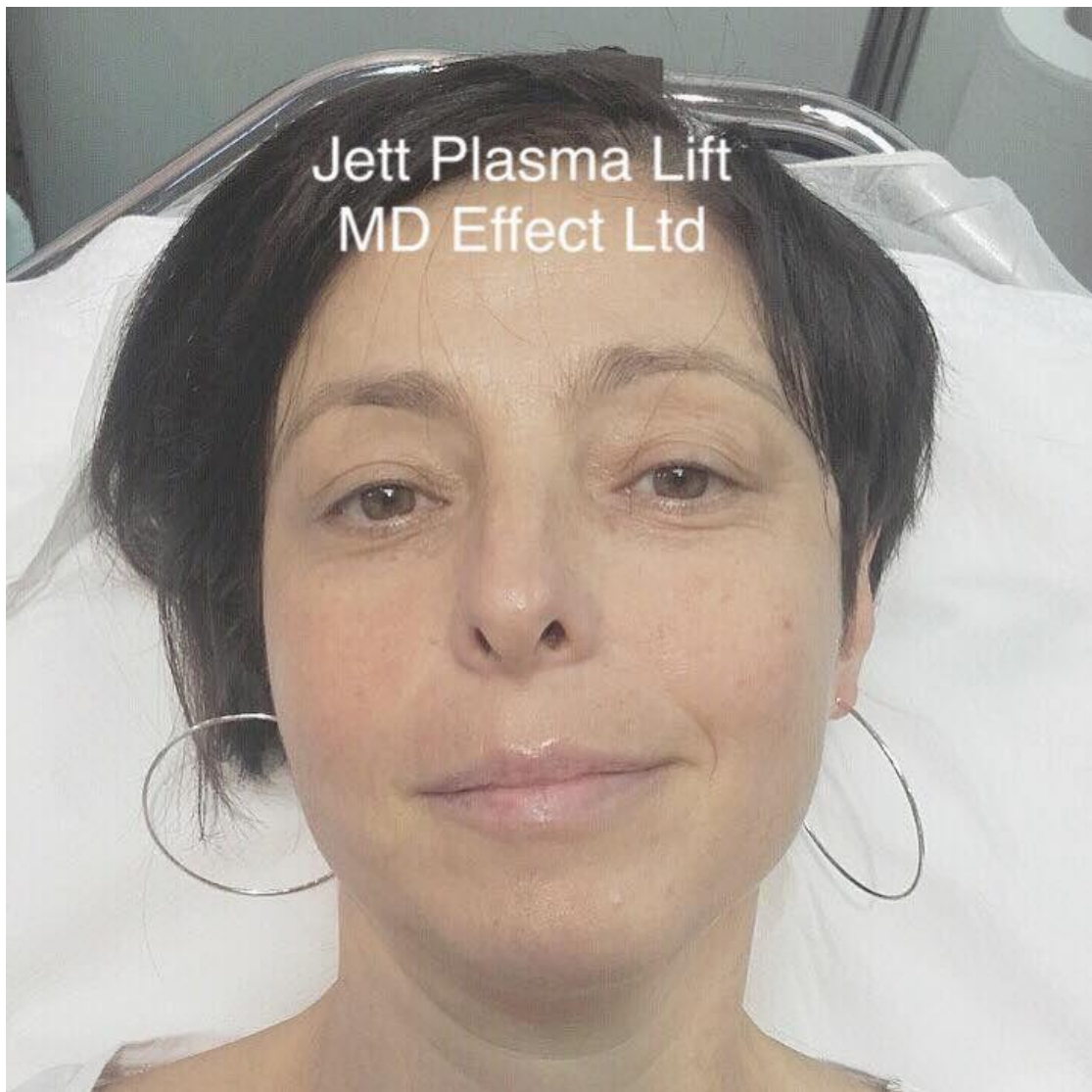The method: Beauty tip, + acute metal nozzle with contact gel; Treat face, neck and neck area

Post treatment: None

Time of healing: None

Side effects: None

Results: Pad, lifting and firming facial contours, relief of wrinkles. Visibly influenced redness.



Treated area: right half of the face and neck area

Patient: Female, 32

Previous undergone aesthetic surgery: None

Anaesthesia: contact gel + hyaluronate

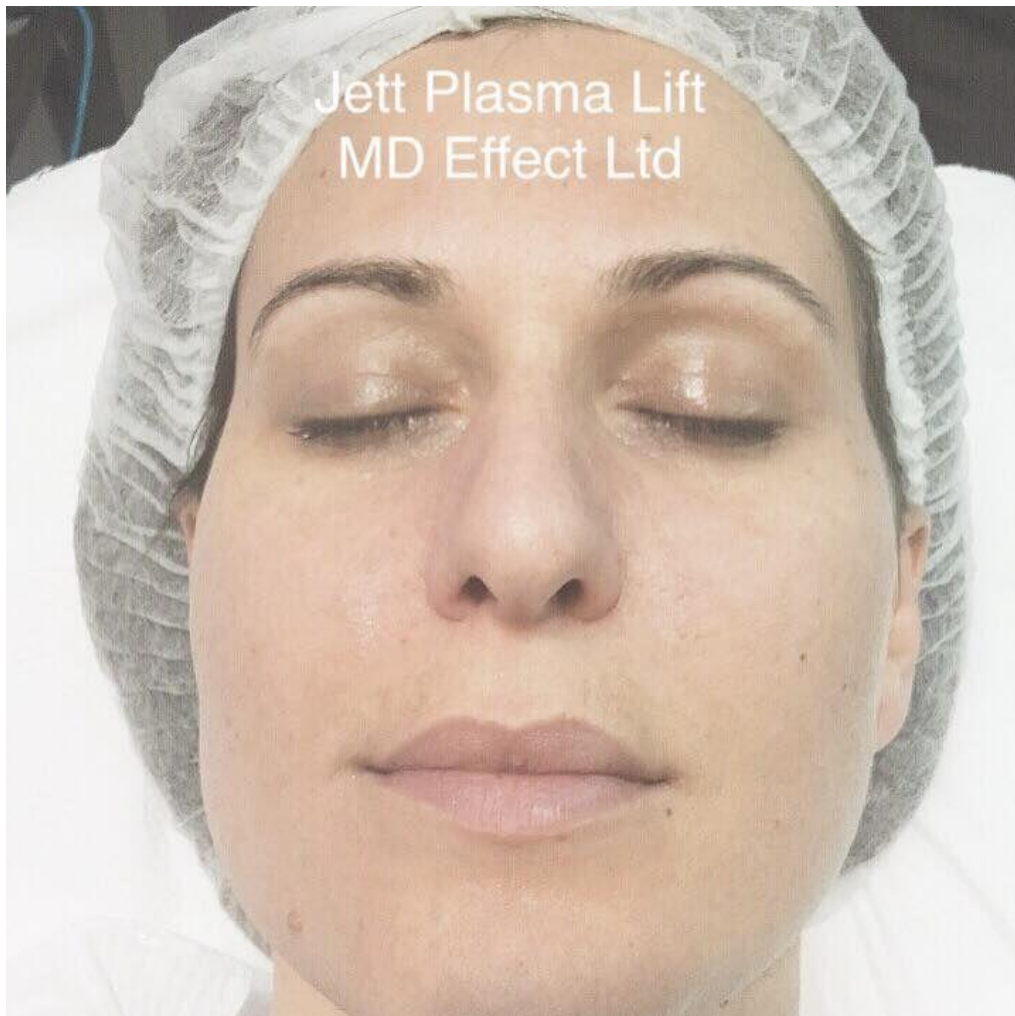The method: Beauty tip with contact gel; Treatment of the right half of the face

Post treatment: None

Time of healing: None

Side effects: None

Results: Pad, lifting the upper eyelid, interference with wrinkles. Visibly influenced redness.



Treated area: Right half of the face, neck and neck area

Patient: Female, 42

Anesthesia: none

Method: Beauty tip, + acute metal nozzle with contact gel; Treatment of face, neck and neck area

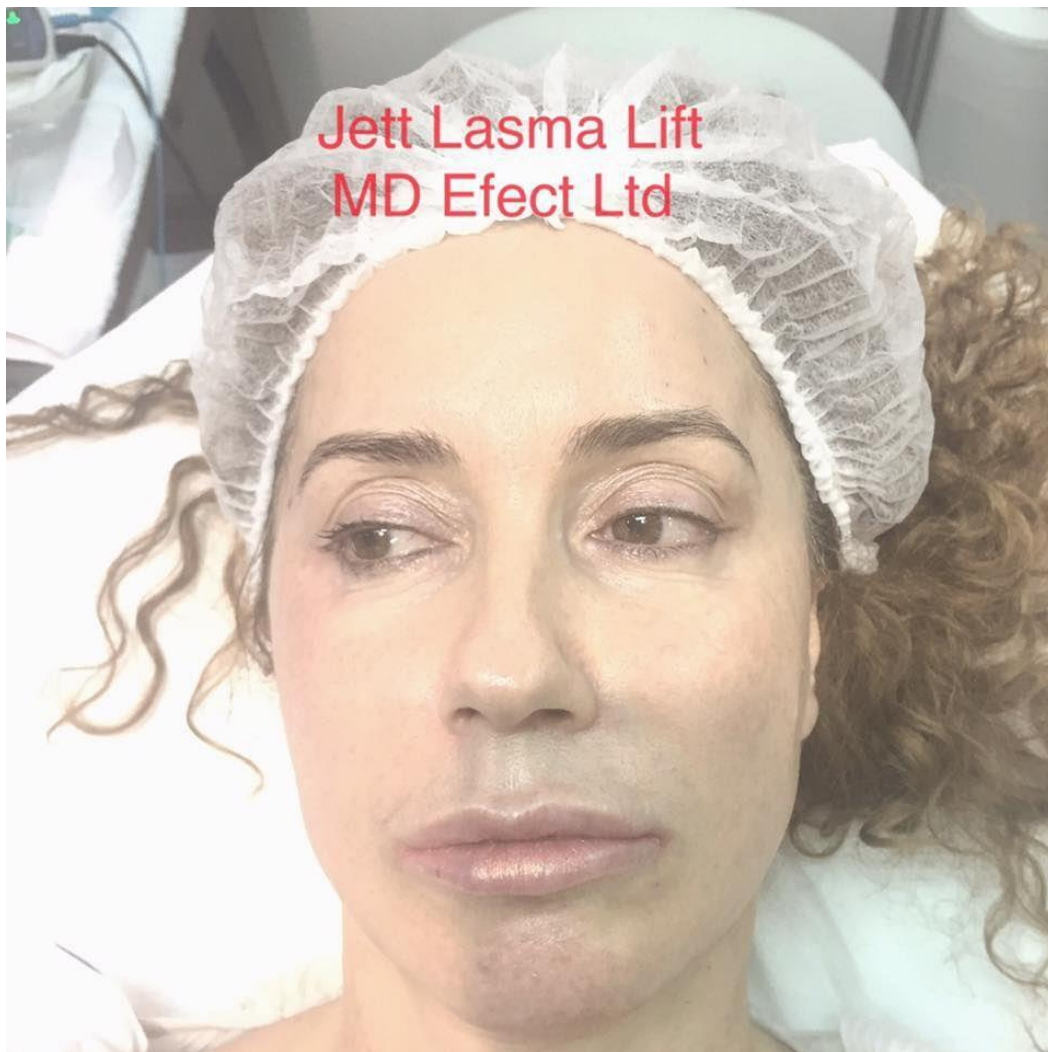Number of procedures: a photo immediately after the procedure

After treatment: no

During the recovery: no

Side effects: none

Results: Pad, lifting and firming facial contours, relief of wrinkles. Visibly influence redness.



Treated area: Right half of the face, neck and neck area

Patient: Female, 35

Anesthesia: none

Method: Beauty tip, + acute metal nozzle with contact gel; Treatment of face, neck and neck area

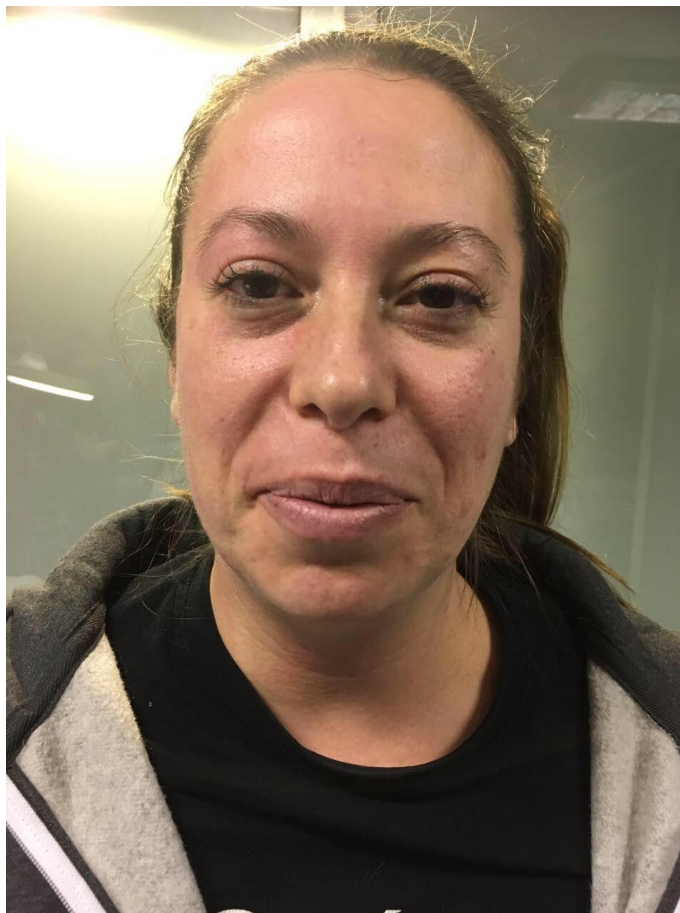Number of procedures: a photo immediately after the procedure

After treatment: no

During the recovery: no

Side effects: none

Results: Pad, lifting and firming facial contours, relief of wrinkles. Visibly influence redness.



Treated area: Face and neck area

Patient: Female, 33

Anesthesia: Lidocaine before the procedure before the microneedling

Method: First - microneedling, after 7 days treatment with JPL

Number of procedures: 1 pc. microneedling and 1. JPL

After treatment: no

Recovery time: 1 week recovery after the microneedling

Side effects: none

Results: lifting and firming facial contours, influence and tightening pores and inflammation. Visibly influence redness.



Treated area: Face, neck and neck area

Patient: Female, 40

Anesthesia: none

Method: Beauty tip, + acute metal nozzle with contact gel; Treatment of face, neck and neck area

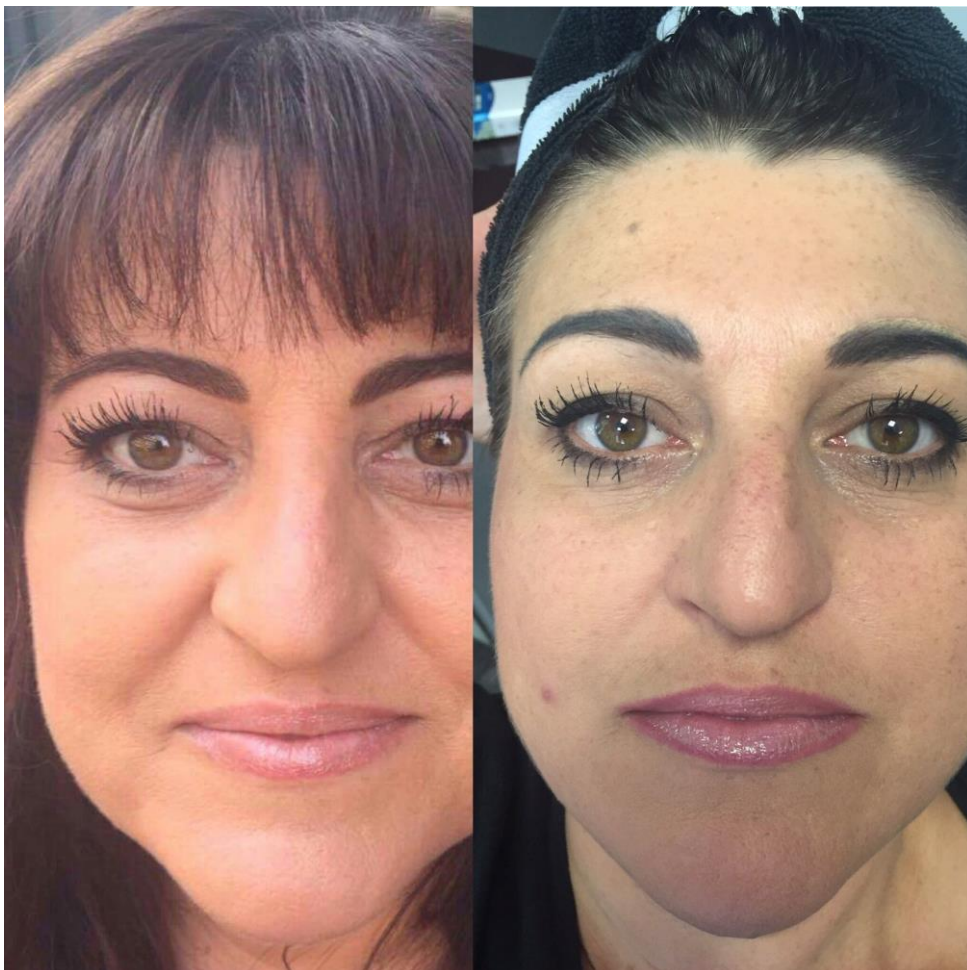
Number of procedures: a photo immediately after the procedure

After treatment: no

During the recovery: no

Side effects: none

Results: Pad, lifting and firming facial contours, relief of wrinkles. Visibly influence



Treated area: Nose old capillary

Patient: Female, 60

Anesthesia: none

Method: sharp white cap with contact gel separation from skin

Number of treatments: 1

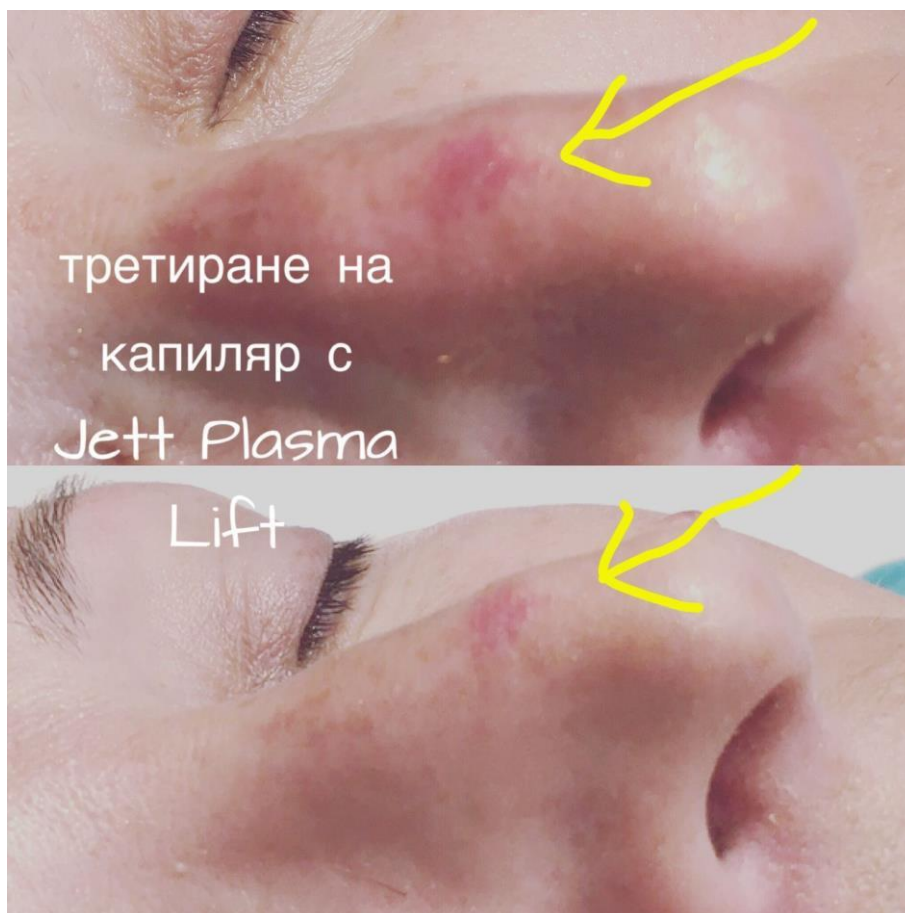Products: contact gel

After treatment: no

Recovery time: 1 week

Side effects: none

Results: visible response and the collection of capillary



Treated area: Right eye

Patient: Male, 40

Anesthesia: none

Method: gold tip

Number of treatments: 1

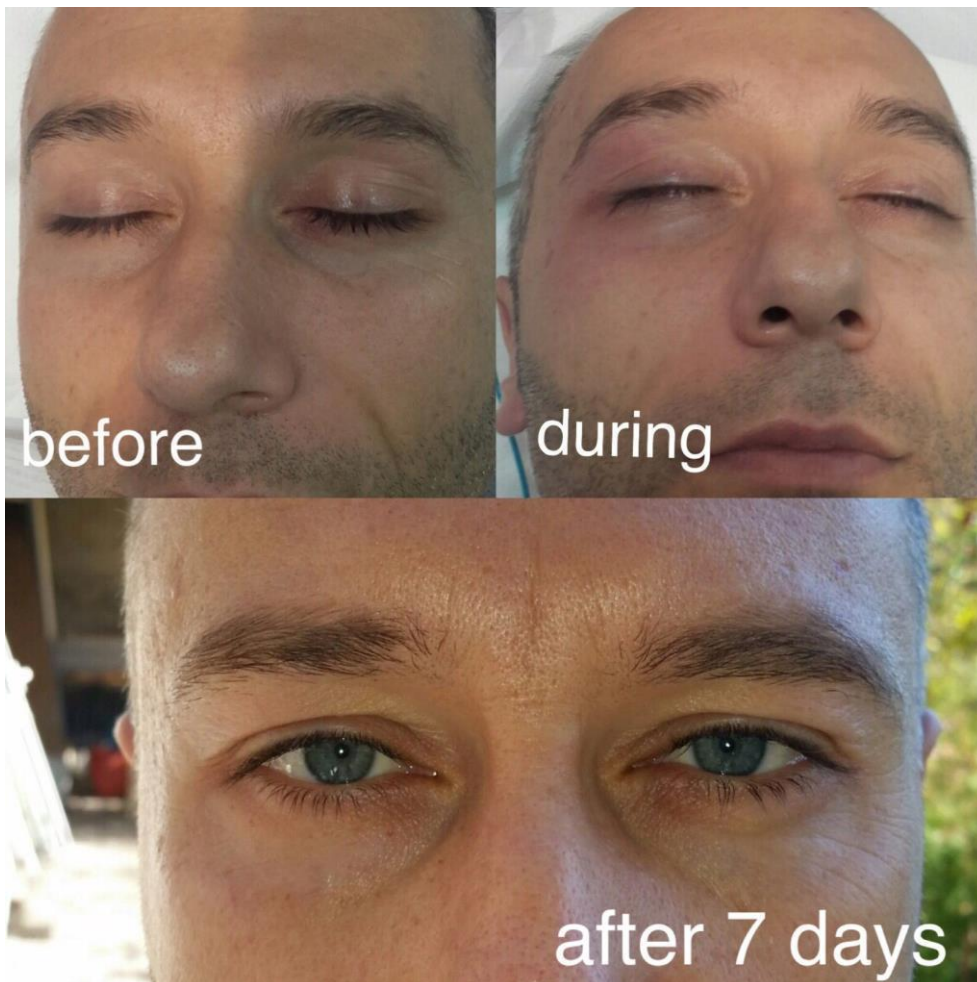Products: None

After treatment: no

Recovery time: 1 week

Side effects: slight swelling and redness

Results: visibly lifting the upper eyelid and smooth wrinkles eye (chanterelle)



Treated area: Face, neck and neck area – rosacea

Patient: Female, 66

Anesthesia: none

Method: Beauty tip, + acute metal nozzle with contact gel; Treatment of face, neck and neck

Number of procedures: a photo immediately after the procedure


Products: contact Gel + Serum capillaries

After treatment: no

During the recovery: no

Side effects: mild redness and swelling of the problem areas

Results: Pad, lifting and firming facial contours, relief of wrinkles. Visibly influence redness, collection and browning of the capillaries.



Treated area: face and neck area

Patient: Female, 45

Anesthesia: none

Method: Beauty tip with contact gel; Treatment of the right half of the face

Number of treatments: 1

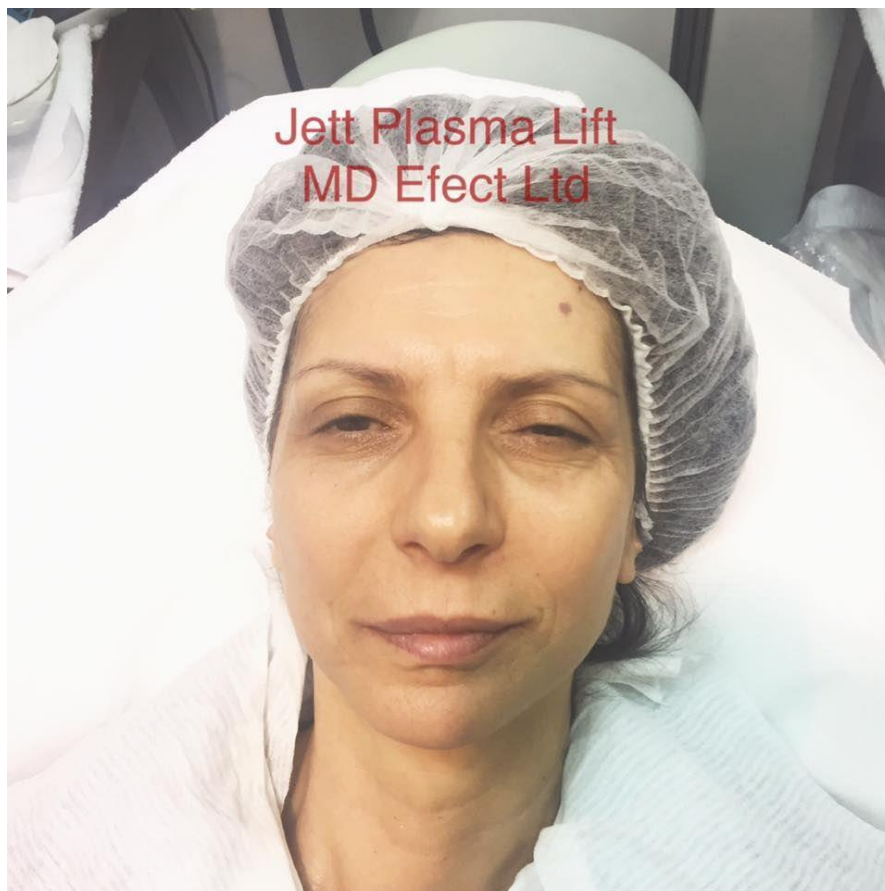Products: contact gel + hyaluronate

After treatment: no

During the recovery: no

Side effects: none

Results: Pad, lifting the upper eyelid, interference with wrinkles. Comment client: She feels like after a fatsialis.



Treated area: Face, neck and neck area

Patient: Female, 55

Anesthesia: none

Method: Beauty tip with contact gel; Treatment of face, neck and neck area

Number of treatments: 3

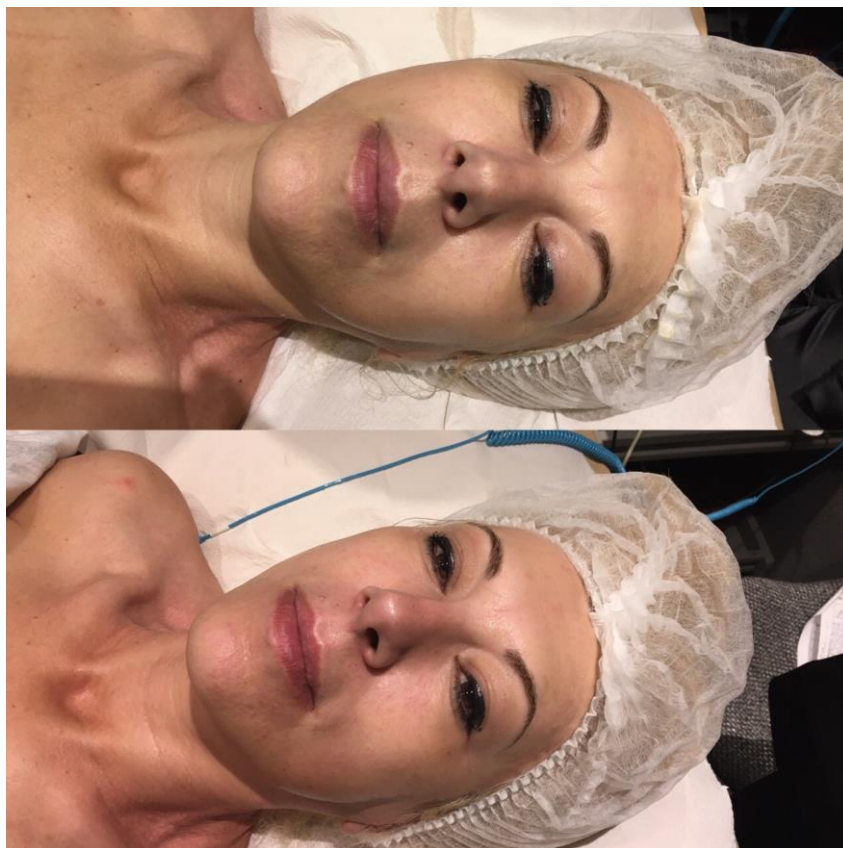Products: contact gel + hyaluronate

After treatment: no

During the recovery: no

Side effects: none

Results: Pad, lifting and firming facial contours, relief of wrinkles.



Treated area: right half of the face and neck with cuperosis

Patient: Female, 48

Anesthesia: none

Method: Beauty tip with contact gel; Treatment of the right half of the face

Number of treatments: 1

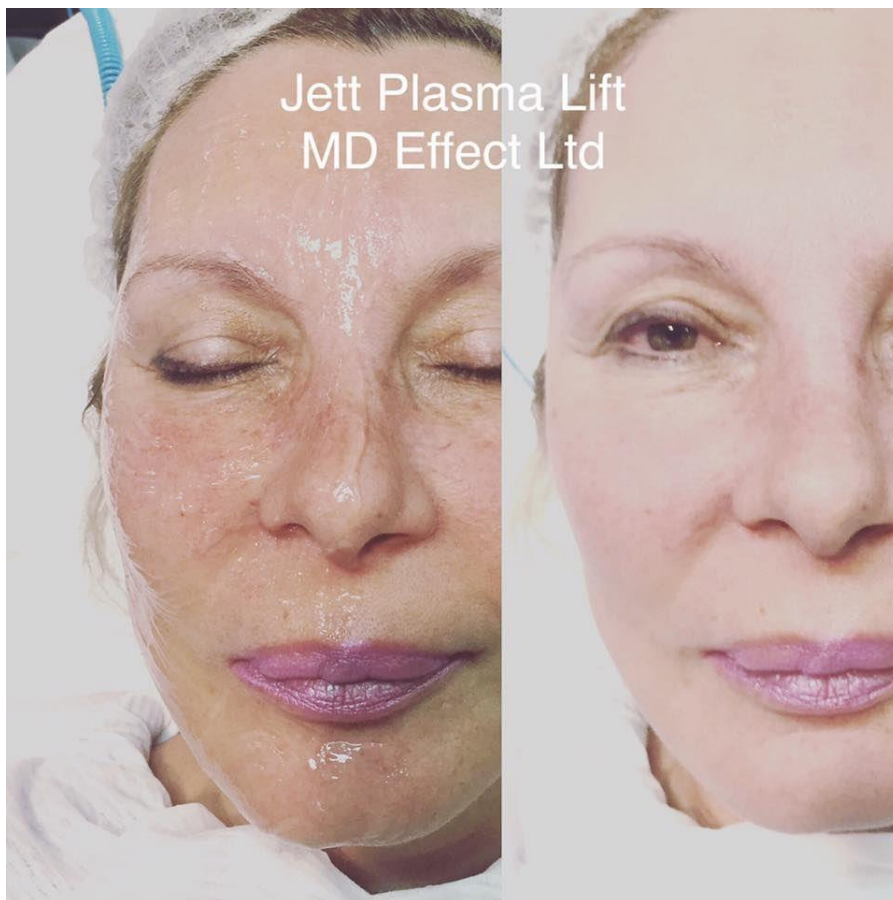Products: contact e gel + hyaluronat

After treatment: no

During the recovery: no

Side effects: none

Results: Pad, lifting the upper eyelid, interference with wrinkles. Visibly influence cuperosis (gathering of capillaries)



Treated area: Flat warts

Patient: female, 30

Anesthesia: none

The metod: Gold nozzle without gel

Number of procedures: 1

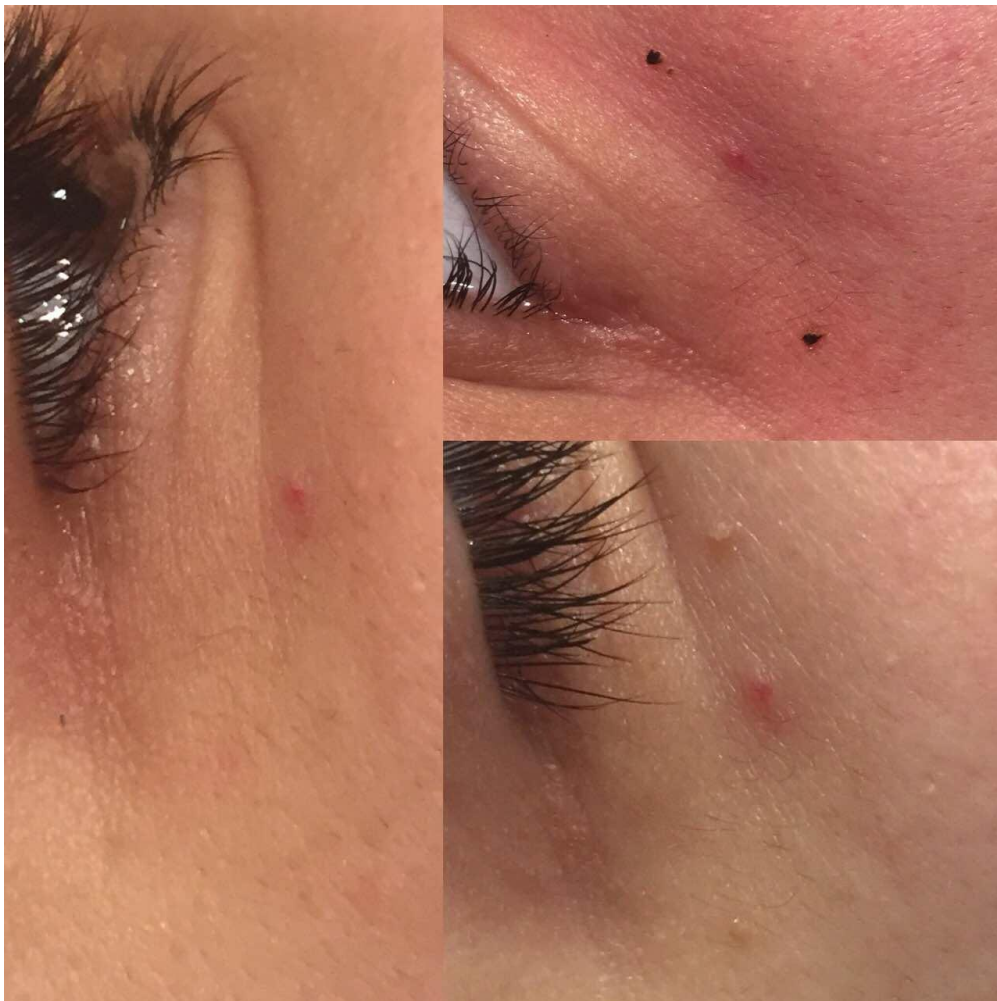Products: none

Post treatment: none

Time of healing: one week

Side Effects: none

Results: Completely healed / covered



2.6 Dr. Doris Wallentin, Vienna

Treated area: upper eye lid

Patient: HF

Previous undergone aesthetic surgery: None

Anaesthesia: about 2 ml Lidocaine

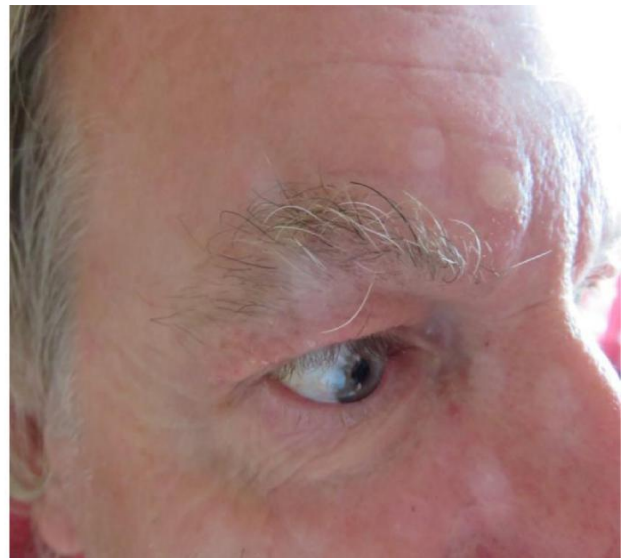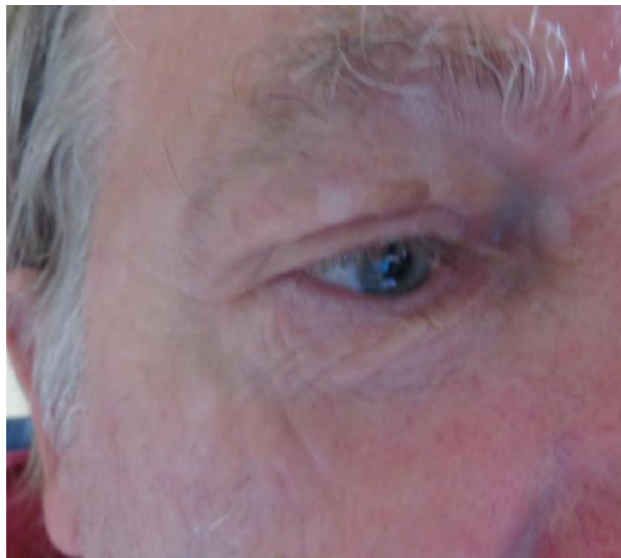The method: scanning, dots

Post treatment: cooling gel

Time of healing: 8 days

Side effects: None

The date of photos: september 2016, 7 days apart



2.7 Dr. Schoppelrey

Treated area: upper eye lid

Patient: female

Previous undergone aesthetic surgery: None

Anaesthesia: local 3 ml Lidocaine

The method: dot-by-dot

Post treatment: Fucidlue creme

Time of healing: 2 weeks

Side effects: hematoma, crusts

2.8 Dr Bhavini Lodaya, Mumbai

Treated area: Infraorbital area and Supraorbital area including Crow's feet area

Previous undergone aesthetic surgery: No Relevant history seen

Anaesthesia: Lignocaine Hydrochloride 2% with either local infiltration technique or nerve block technique was used.

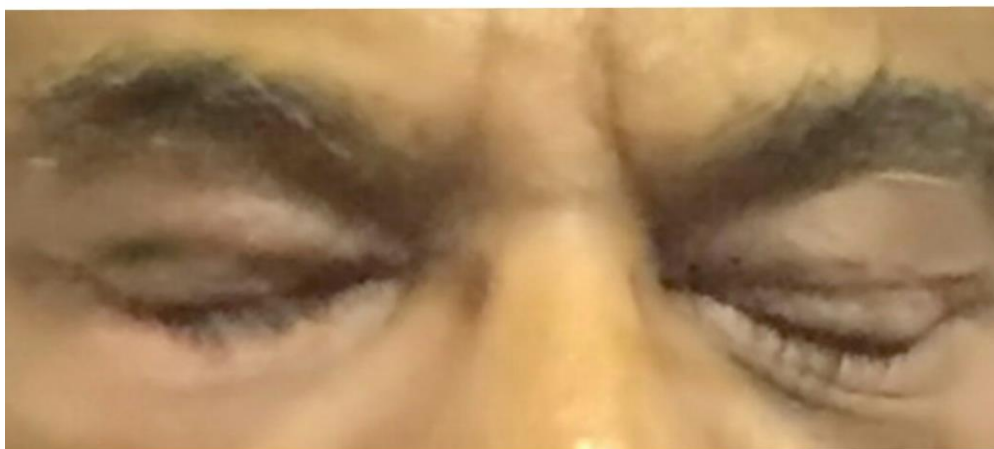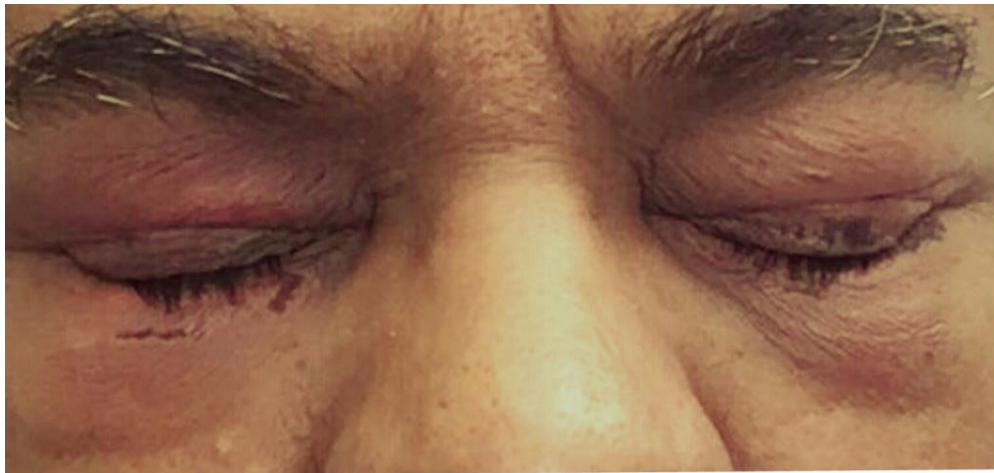The method: scanning and after dot-by-dot both method was used

Post treatment: 2 month mandatory use of sunglasses and Hyaluronic gel + vitamin C home care and SPF protection.

Time of healing: 4-6 days (Erythema followed by edema which subsided in 4-6 days)

Side effects: None

Date of photos: before, 1 month after



2.9 Yuva Cosmoderm,Dr Trimbake

Treated area: Infraorbital area and Supraorbital area including Crow's feet area

Previous undergone aesthetic surgery: No Relevant history seen

Anaesthesia: Lignocaine Hydrochloride 2% with either local infiltration technique or nerve block technique was used.

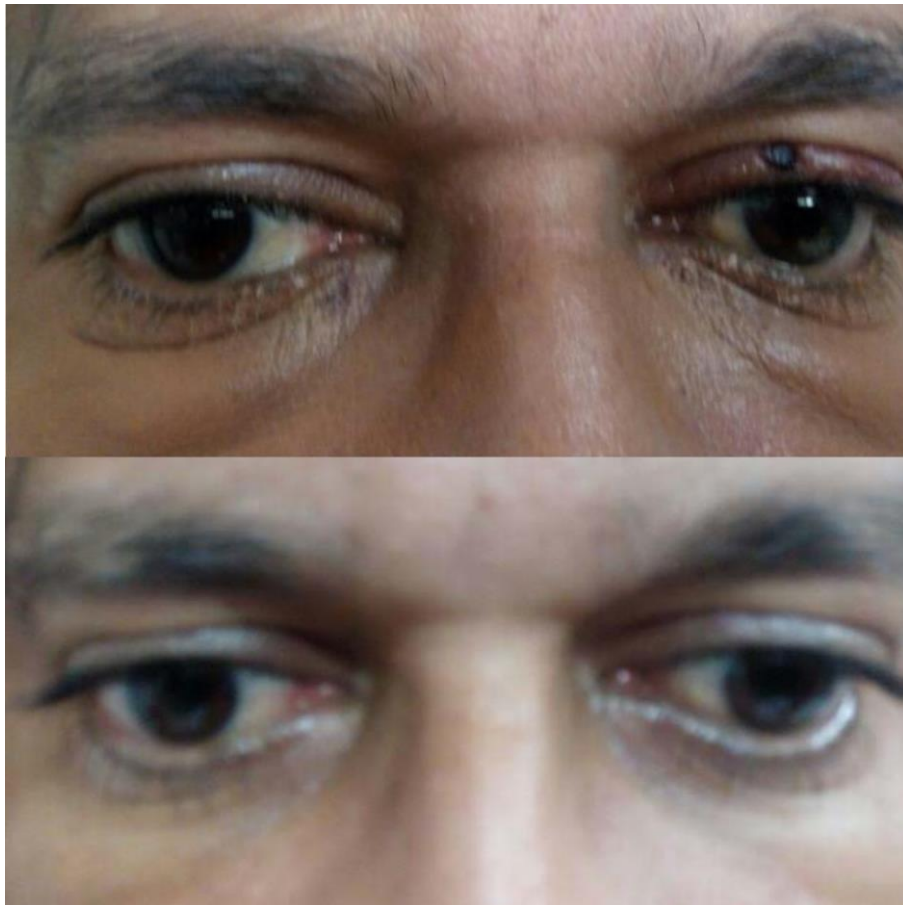The method: scanning and after dot-by-dot both method was used

Post treatment: 2 month mandatory use of sunglasses and Hyaluronic gel + vitamin C home care and SPF protection.

Time of healing: 4-6 days (Erythema followed by edema which subsided in 4-6 days)

Side effects: None

Date of photos: before, 1 month after



2.10 Joshi Hospital,Dr Mutalik

Treated area: Infraorbital area and Supraorbital area including Crow's feet area

Previous undergone aesthetic surgery: No Relevant history seen

Anaesthesia: Lignocaine Hydrochloride 2% with either local infiltration technique or nerve block technique was used.

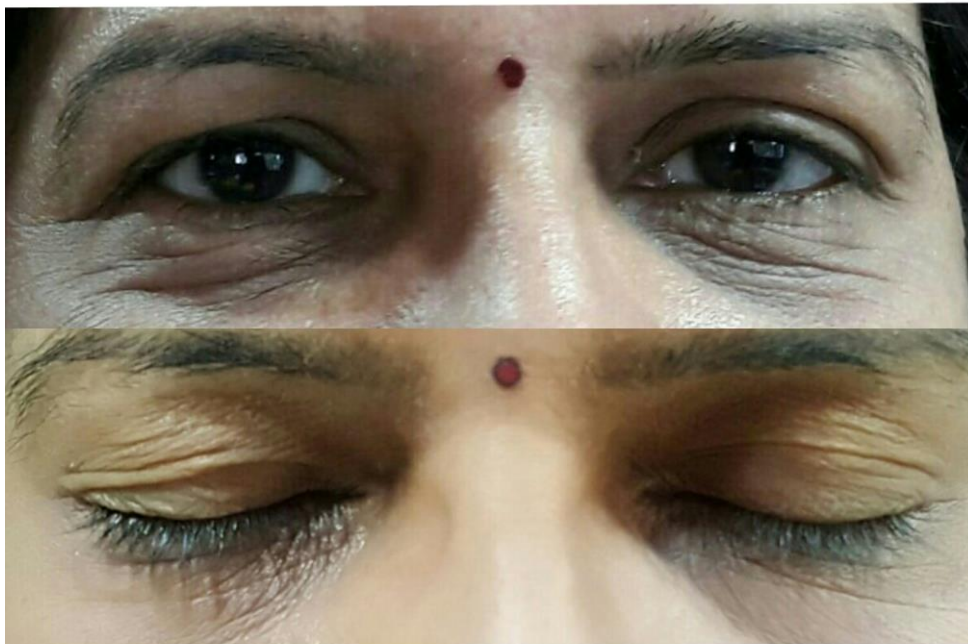The method: scanning and after dot-by-dot both method was used

Post treatment: 2 month mandatory use of sunglasses and Hyaluronic gel + vitamin C home care and SPF protection.

Time of healing: 4-6 days (Erythema followed by edema which subsided in 4-6 days)

Side effects: None

Date of photos: before, 1 month after



3. Fibroma

3.1 Irena Pluhar, Praxis für Ästhetische Dermatologie, Sauerlach - Germany

Treated area: Shoulder

Patient: Male, 41

Previous undergone aesthetic surgery: None

Anaesthesia: No – (Ring anaesthesia)

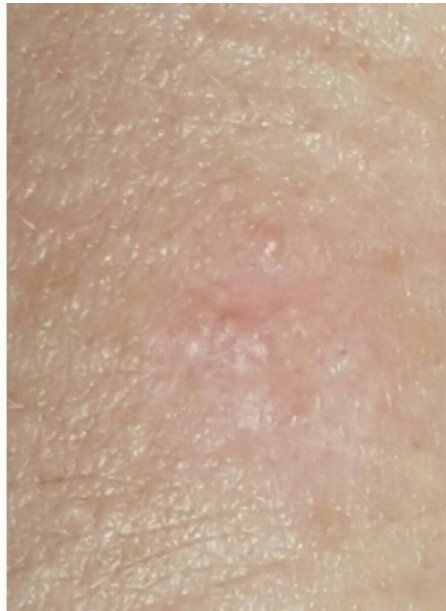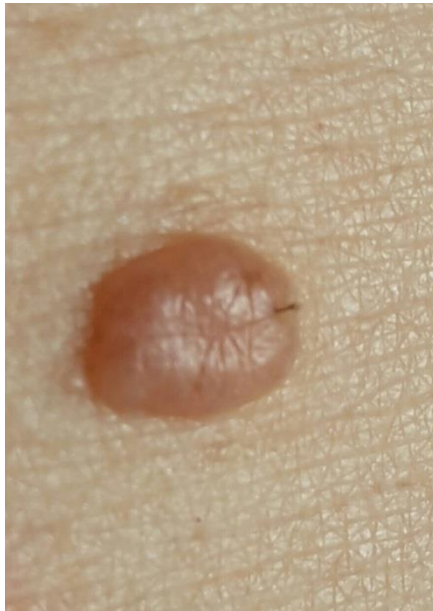The method: Scanning until the upper layer is burnt, remove it and repeat with lower layer

Post treatment: Antiseptic gel

Time of healing: After 1 days crusts, after two week regenerated skin)

Side effects: None

The date of photos: First photo 10.10.2017, second photo after approximately 2 month



3.2 Veronika Flašárová MD., Dermi Clinic, Brno, Czech Republic

Treated area: Neck

Patient: Female, 65

Previous undergone aesthetic surgery: None

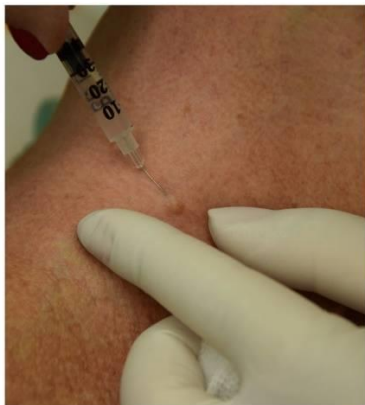Anaesthesia: Local injection, Lidocain 5%

The method: Scanning until it is burnt, remove it and repeat with lower layer

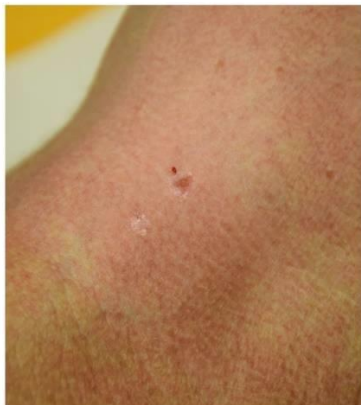Post treatment: Sun protection for one month (SPF 50+), regenerating cream

Time of healing: three days

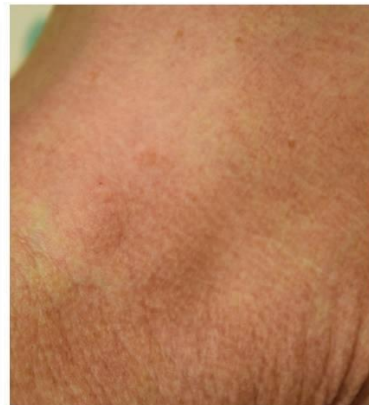Side effects: None



Before



Immediately
after



One week
after

Treated area: Neck

Patient: Female, 76

Previous undergone aesthetic surgery: None

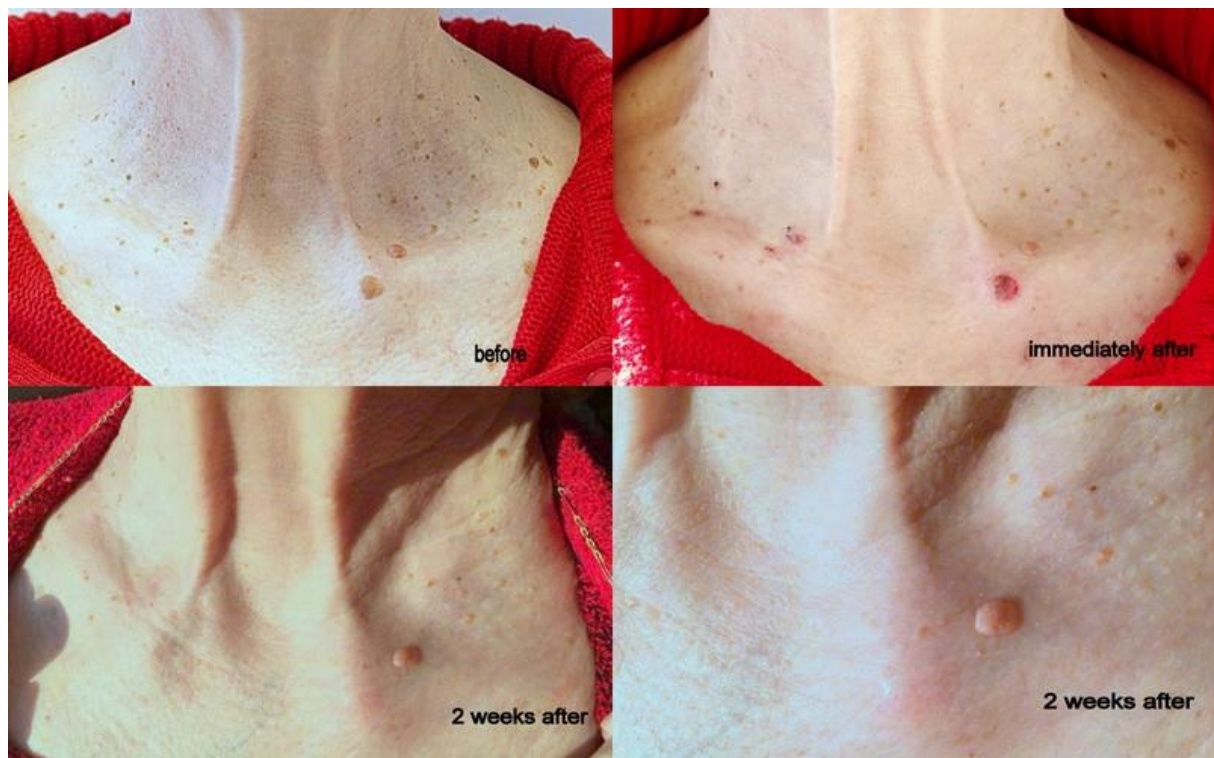Anaesthesia: Local injection, Lidocain 5%

The method: Scanning until it is burnt, remove it and repeat with lower layer

Post treatment: Sun protection for one month (SPF 50+), antibiotic cream if inflamed

Time of healing: 10 days

Side effects: inflammation



4. Seborrheic Keratosis

4.1 Dr. Mohammad Ghazzawi / Derma Right / Amman – Jordan

Treated area: Left temple

Patient: Female, 24

Previous undergone aesthetic surgery: None

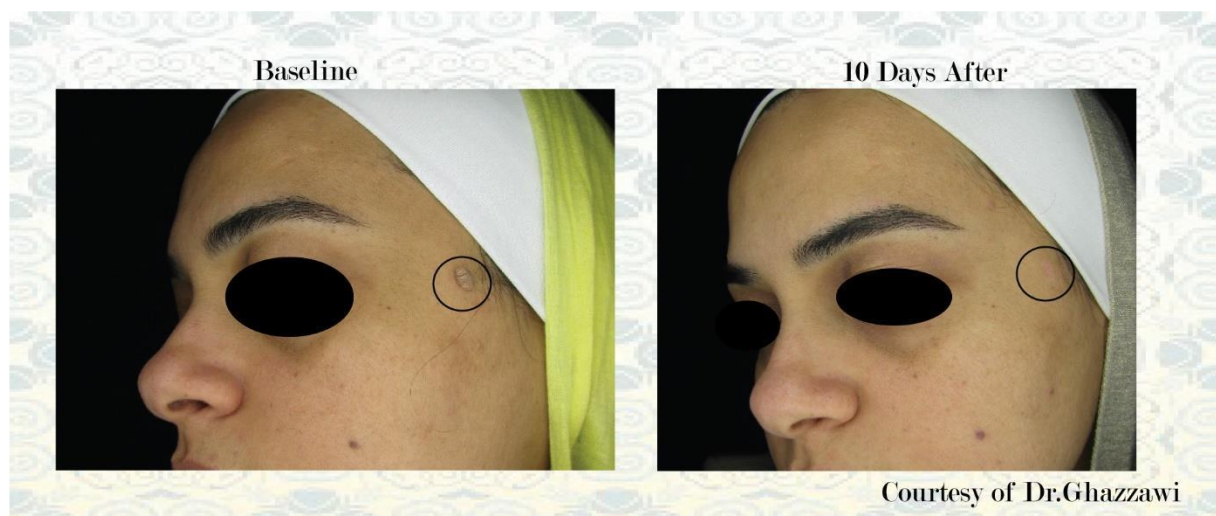Anaesthesia: Infiltration with lidocaine 2%

The method: Partial debulking with Razor, followed with scanning

Post treatment: Vaseline

Time of healing: 3 Days

Side effects: None



5. Skin Tags

5.1 Dr. Mohammad Ghazzawi / Derma Right / Amman – Jordan

Treated area: Right Eyelids, Upper and Lower

Patient: Male, 31

Previous undergone aesthetic surgery: None

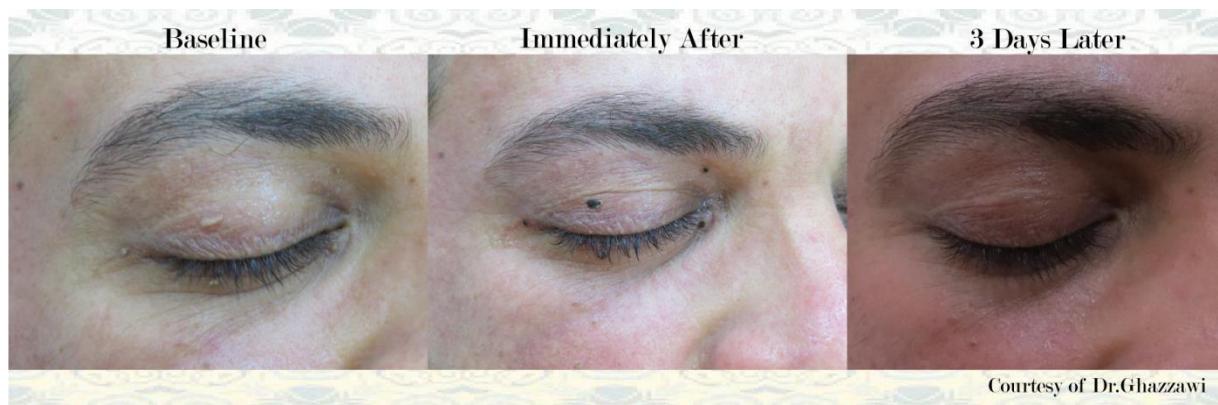Anaesthesia: None

The method: Scanning

Post treatment: Vaseline

Time of healing: 3 Days

Side effects: None



6. Hemangioma

6.1 Irena Pluhar, Praxis für Ästhetische Dermatologie, Sauerlach – Germany

Treated area: Thorax

Patient: Male, 41

Previous undergone aesthetic surgery: None

Anaesthesia: local Lidocain-Crème with 20% Lidocain and 5 % Tetracaine with occlusion

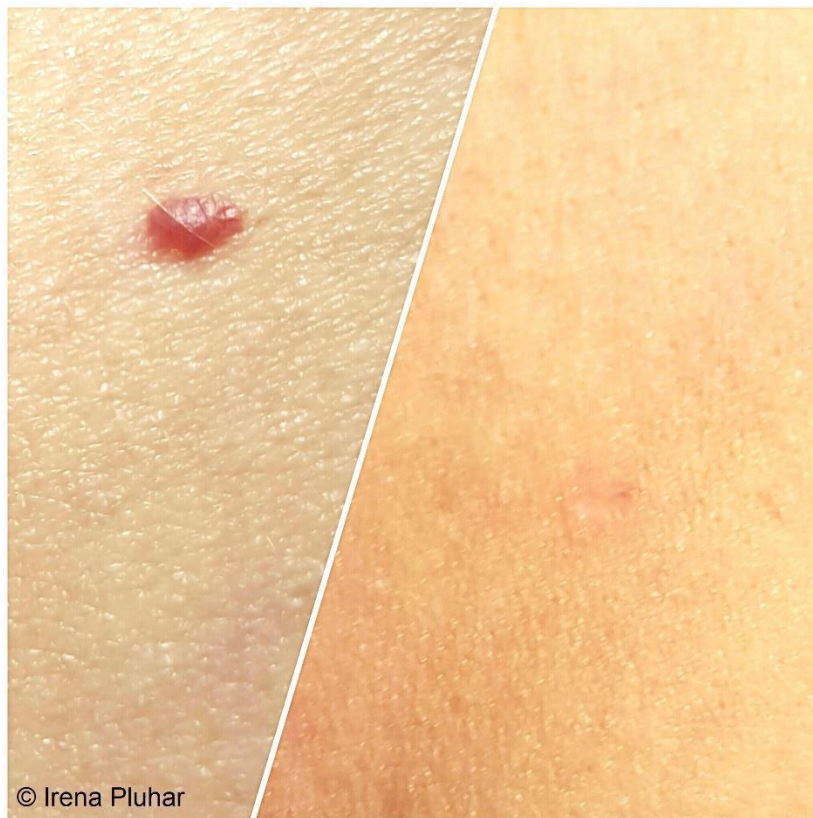The method: 1 minutes of scanning

Post treatment: Wash only with nuclear soap, as long as the crust exists. After washing, lightly dab with alcohol-free disinfectant. In case of strong sensitivity and redness, antiseptic gel

Time of healing: After 2 days crusts, after one week regenerated skin

Side effects: None

The date of photos: 13.01.2017, second photo after approximately 2 Weeks



7. Face Lipomas

7.1 Veronika Flašárová MD., Dermi Clinic, Brno, Czech Republic

Treated area: Neck

Patient: Female, 40

Previous undergone aesthetic surgery: None

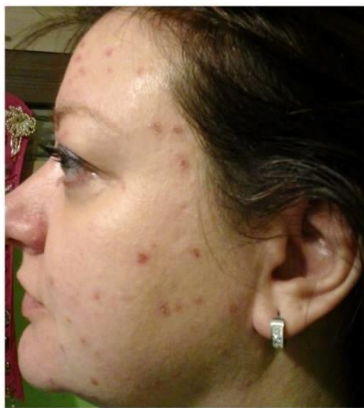Anaesthesia: Local injection, Lidocain 5%

The method: Scanning until the raised portion is burnt, eventually remove fat by needle

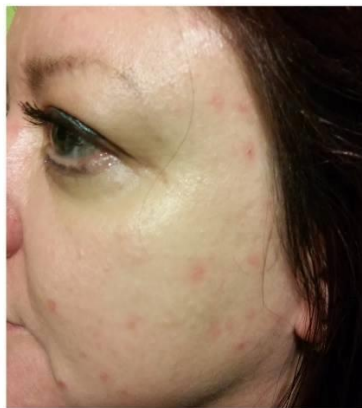Post treatment: Sun protection for one month (SPF 50+), regenerating cream

Time of healing: One week

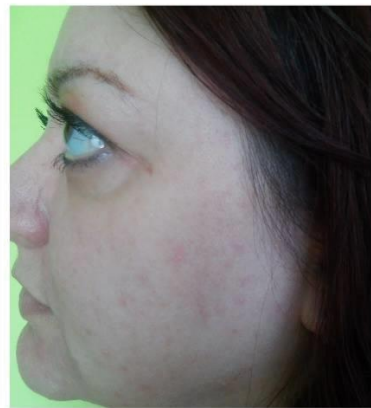Side effects: None



Before



One week
after



Three weeks
after

Treated area: Neck

Patient: Female, 40

Previous undergone aesthetic surgery: None

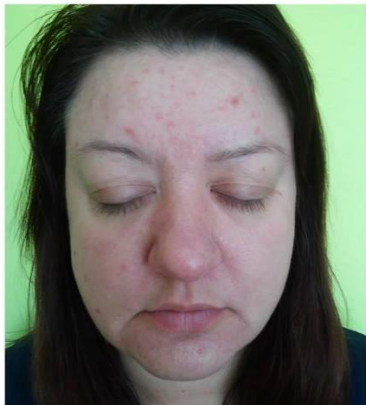Anaesthesia: Local injection, Lidocain 5%

The method: Scanning until the raised portion is burnt, eventually remove fat by needle

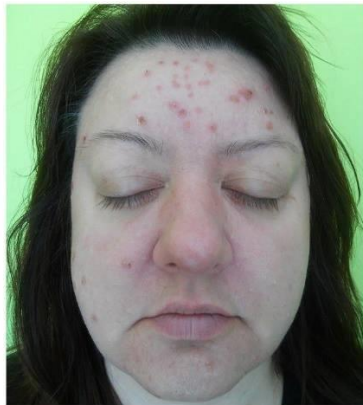Post treatment: Sun protection for one month (SPF 50+), regenerating cream

Time of healing: One week

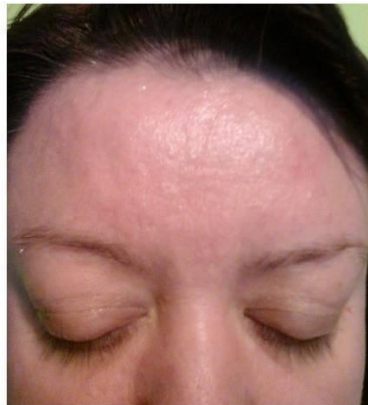Side effects: None



Before



Two days
after



Two months
after

8. Telangiectasia

8.1 Veronika Flašárová MD., Dermi Clinic, Brno, Czech Republic

Treated area: nose dorsum

Patient: Female, 23

Previous undergone aesthetic surgery: None

Anaesthesia: Local injection, Lidocain 5%

The method: dot by dot along the vein, 2 millimetres distance between dots


Post treatment: Sun protection for one month (sunglasses, SPF 50+)

Time of healing: One week

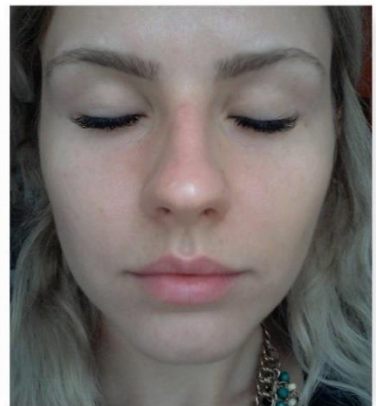
Side effects: None



Before



Three days
after



Three weeks
after

9. Nasolabial wrinkles

9.1 Veronika Flašárová MD., Dermi Clinic, Brno, Czech Republic

Treated area: nasolabial wrinkles

Patient: Female, 63

Previous undergone aesthetic surgery: None

Anaesthesia: Local injection, Lidocain 5%

The method: scanning for 5 minutes, until the skin changes its colour

Post treatment: Sun protection for one month (sunglasses, SPF 50+), application of Jett LiftVital serum for one month

Time of healing: One week

Side effects: None

The date of photos: Before, Immediately after, 2 months after

