



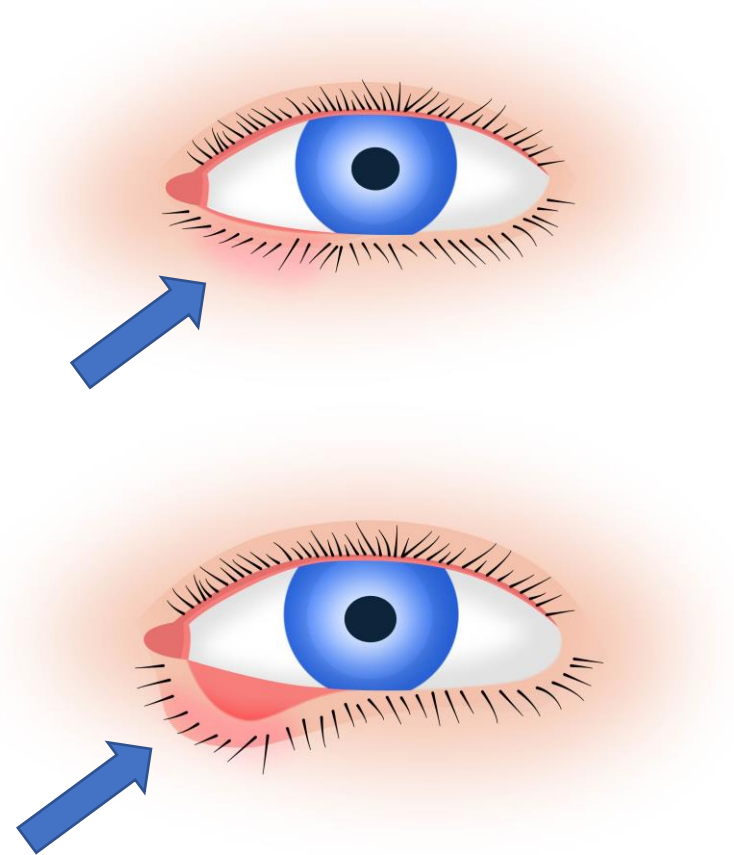
Ectropion

Treated by JETT PLASMA LIFT MEDICAL



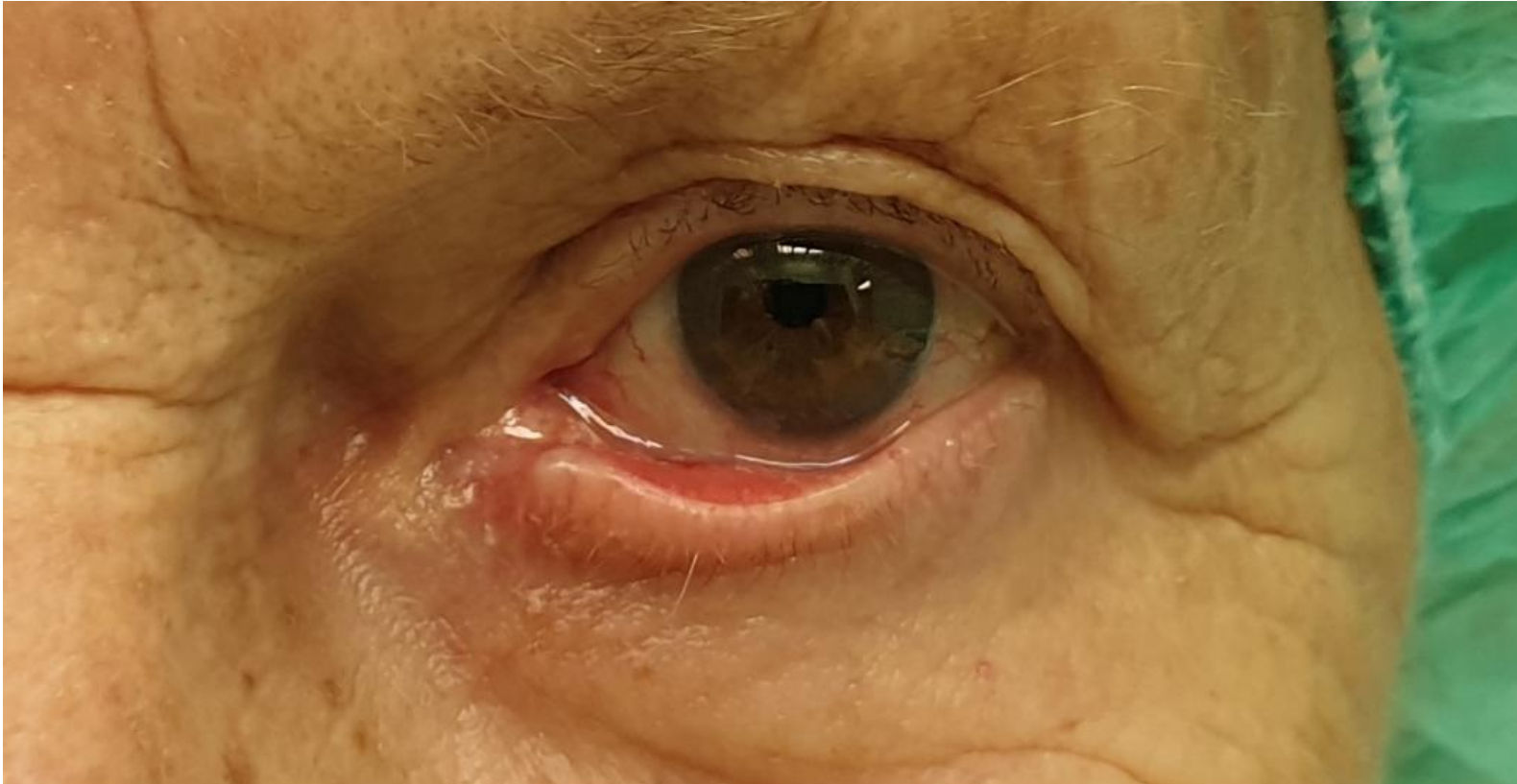
Case

- Patient, 91 years old
- Diagnosis: Ectropion at the the tear point of the lower eyelid on the right
- Performed operation – **without sufficient effect**
- thereafter the JETT PLASMA treatment was applied 2 weeks after operation
- Effect after JETT PLASMA treatment is more than satisfactory





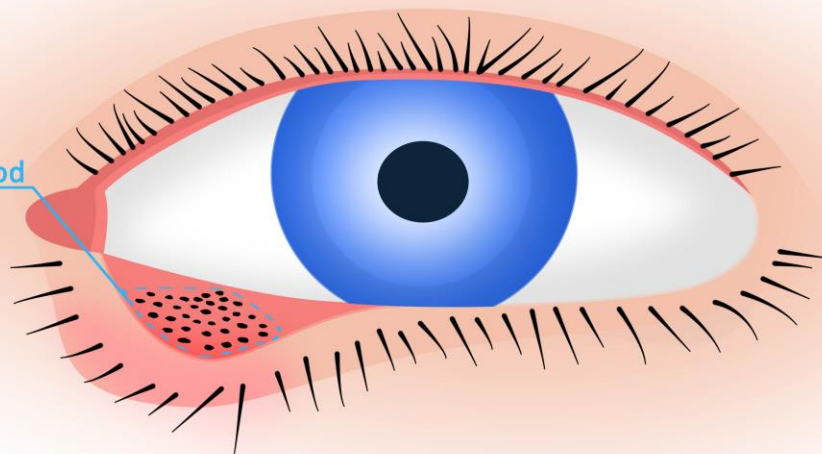
Before treatment





Treatment protocol

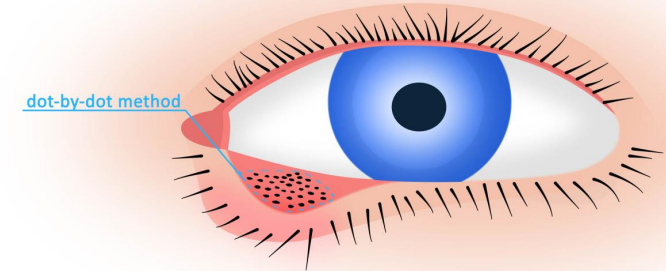
dot-by-dot method





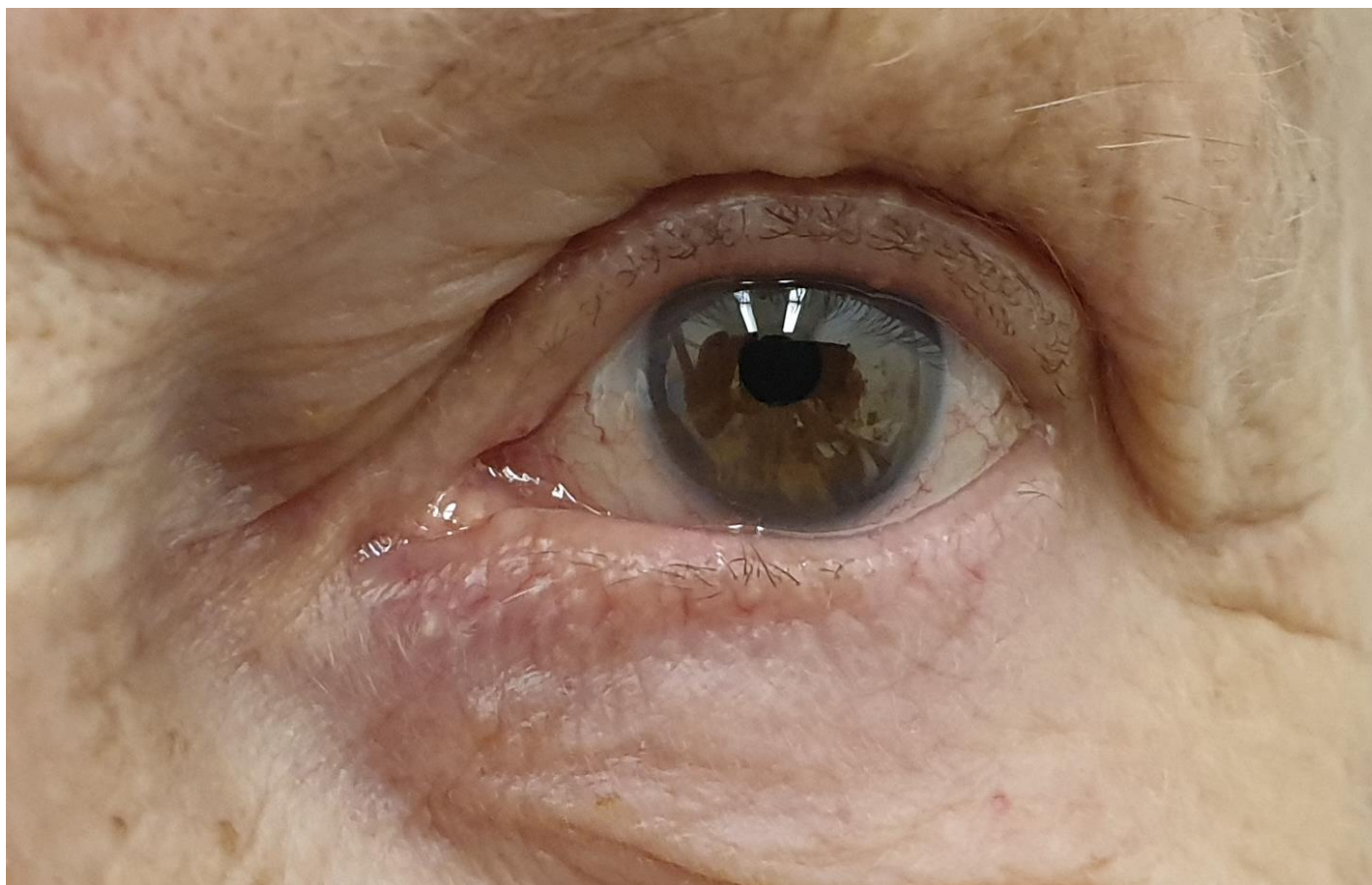
Treatment protocol

- Use dot-by-dot method
- Doctor modified the JETT protocol according to patient's condition and combination with surgical treatment
- The dot-by-dot method was applied only in the inner side of the eyelid, inner corner – as on the picture.





After 1,5 month





COMPEX, spol. s r. o.

A/ Palackého tr. 105, 612 00 Brno

E/ info@jett.eu

WWW.JETT.EU